Eur J Plast Surg (2013) 36:69–74
DOI 10.1007/s00238-012-0759-2

ORIGINAL PAPER

Orbital exenteration for the treatment of advanced periocular skin cancer

Arif Turkmen · Metin Temel · Ayla Gokce · Mehmet Bekerecioglu

Received: 27 February 2012 / Accepted: 20 August 2012 / Published online: 9 September 2012

Abstract
Background Orbital exenteration is a surgical procedure which typically involves removal of the entire contents of the orbit including the periorbit, appendages, eyelids and, sometimes, a varying amount of surrounding skin. This operation is reserved for the treatment of potentially life-threatening malignancies arising from the orbit, paranasal sinuses or periocular skin. We have reviewed the cases that underwent orbital exenteration and reconstructive techniques for closing the defect.
Methods Twenty-six patients, who underwent orbital exenteration from April 2001 to September 2010, were retrospectively analyzed, and data including patient demographics, tumor location and characteristics were collected. The reconstructive techniques were reviewed.
Results The study consisted of 16 males and 10 females with a mean age of 68.8 years (range 50 to 89 years). Fourteen left and 12 right exenterations were performed. The location of the tumor was most commonly at the medial canthus followed by the lateral canthus, nose, eyelids and cheek. Twenty-one out of 26 cases (80.76 %) were basal cell carcinomas and the remaining (19.23 %) were squamous cell carcinomas. Reconstructive techniques included superficial temporal artery-based forehead flap (73.07 %), the scalp flap (11.53 %), and the latissimus dorsi free flap (15.58 %).
Conclusions Among various options available for the reconstruction of the orbital exenteration, the superficial temporal artery-based forehead flap is a relatively simple one and the final outcome, according to our experience, is comparable to that of more complex flap procedures, providing an acceptable cosmetic result with minimal donor site morbidity and short operating time.
Level of Evidence: Level IV, therapeutic study.

Keywords Orbital exenteration · Basal cell carcinoma · Forehead flap · Superficial temporal artery-based island flap

A. Turkmen (✉) · M. Temel · A. Gokce · M. Bekerecioglu
Department of Plastic, Reconstructive and Aesthetic Surgery,
Gaziantep University Faculty of Medicine,
Gaziantep, Turkey
e-mail: turkmenarif@yahoo.com

Introduction

Orbital exenteration, first described by George Bartisch in 1586, is a complex disfiguring procedure reserved for the treatment of locally invasive advanced eyelid skin cancer, potentially life-threatening orbital neoplasms or may rarely be performed for non-neoplastic disease. It is performed as an infrequent procedure worldwide [1, 2].

Tumors or diseases of orbit may be originated primarily from the orbit or involved from adjacent tissues or metastatic sources. Two to four percent of the periocular skin cancers infiltrate into the orbit [3]. Fifty to sixty percent of orbital exenterations are performed for tumors in the eyelid or periocular skin which are mostly basal cell carcinomas (BCC) and squamous cell carcinomas (SCC), followed by sebaceous-gland carcinomas and melanomas [4–6]. The cancer of the eyelids or periorbital skin can penetrate through the orbital septum and infiltrate the eyeball and intraconal or extraconal tissues.

Orbital *exenteration* may provide a cure for the local invasive advanced periorbital skin cancer which has spread through the orbital septum; however, this procedure results with a significant deformity. Furthermore, the patients generally have significant comorbidities and may previously have undergone surgery and/or radiotherapy. Hence, the reconstruction of the orbital defect is a great challenge. Success of the treatment depends on obtaining tumor-free surgical margins at the surgery, before any distant

metastasis, in case of SCC, develops. The reconstruction should allow early detection of recurrent disease and result with an acceptable aesthetic outcome [7]. Various reconstructive options are available, including secondary healing of the defect, skin grafts, local flaps, and distant flaps depending on the size of the defect [7–14].

The aim of this study was to assess the role of the extended orbital exenteration in the treatment of advanced periocular skin cancers and the use and outcome of the superficial temporal artery-based forehead flap in reconstruction of the resultant defect.

We have reviewed the patients who underwent orbital exenteration at our clinic over a 9-year period.

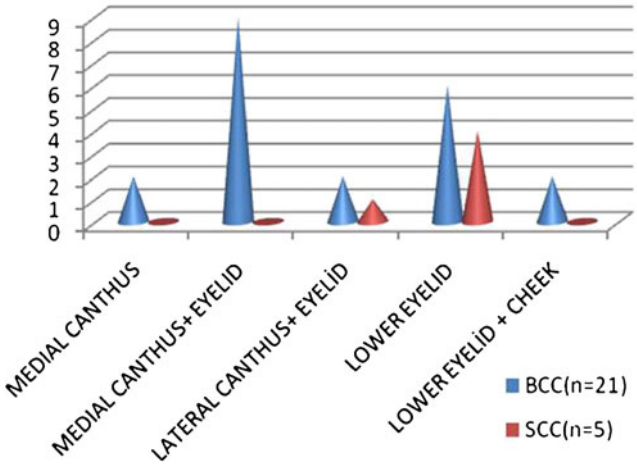

Fig. 1 Histological diagnosis and localisations of the tumors

Patients and methods

Twenty-six patients who underwent orbital exenteration during the 9-year period (2001–2010) for locally advanced non-melanotic skin cancers at the orbital region infiltrating the orbit and the orbital walls were retrospectively analyzed, and data including patient demographics, presenting complaints, procedure performed, information of histological diagnosis and outcome were collected. Pre-existing comorbidities were noted and patients classified according to the American Society of Anaesthesiologists (ASA) grade. The duration of follow-up and recurrence of tumor were also recorded.

Surgical procedure

In case of highly aggressive tumor, the tumor was excised with 1-cm surgical margins and an additional specimen for frozen section was taken from the deepest part of any suspicious tissue after en block removal of the tumor. The resultant defect was closed with either superficial temporal artery-based forehead flap, scalp flap, or latissimus dorsi free flap. Donor site on the forehead was grafted.

Results

The study population consisted of 16 males and 10 females with a mean age of 68.8 years (range 50–89 years). Fourteen left and 12 right exenterations were performed. The tumors were located most commonly at the medial canthus, followed by the lateral canthus, nose, eyelids, and cheek (Fig. 1). Nine patients had computed tomography (CT) scan and 16 patients had magnetic resonance (MR) imaging preoperatively.

All of the patients had recurrent disease and had previously undergone a surgical procedure; average number of previous surgeries was 3.8 times (range, 3–8). Five of the patients had received radiotherapy for the treatment of local recurrence of the tumor before orbital exenteration. There was extensive BCC on the half the face on a patient. Furthermore, maggots were crawling on the center of the lesion. Eleven (42.3 %) patients were classified as ASA grade II or more (Fig. 2).

Twenty-one out of 26 patients (80.76 %) underwent orbital exenteration and five of them (19.23 %) underwent extended orbital exenteration, which refers to partial maxillectomy in addition to orbital exenteration. Orbital floor was reconstructed with a non-absorbable polypropylene mesh (Prolene, Ethicon, New Jersey, USA) to prevent soft tissue herniation into the maxillary sinus in four cases. The temporal bone and the dura excision were performed in addition to extended orbital exenteration in a case. The histopathological examination of surgical specimens revealed that 24 out of 26 patients had tumor-free surgical margins. Of the tumors, 80.76 % were basal cell carcinomas; the remaining 19.23 % of the tumors were squamous cell carcinomas (Fig. 3).

The reconstruction was achieved with the superficial temporal artery-based forehead flap on 19 patients (73.07 %; Figs. 2 and 3), the scalp flap on 3 patients (11.53 %; Fig. 4) and the latissimus dorsi free flap on 4 patients (15.38 %; Fig. 5). There was no flap necrosis; however, partial graft healing problem developed in three patients which were treated conservatively. The mean duration of hospital stay was 6.3 days (5 to 11 days) for the superficial temporal artery-based forehead flap and 10.4 days (8–15 days) for the latissimus dorsi free flap. During the first year of the follow-up period, the patients were examined every 6 weeks and CT investigation of the orbital cavity was obtained every 6 months. After the first year, the patients visited the clinic every 3 months and every 6 months after the second year. CT scan was obtained once a year. Mean follow-up period was 3.9 years (6–89 months).

Only one patient had local recurrence of BCC at the medial canthus region, 16 months following the exenteration procedure although histopathologic result of the surgical specimen was tumor-free at surgical margin.

Fig. 2 Patient with recurrent basal cell carcinoma. View following exenteration, reconstruction with STA flap and split thickness skin graft to donor area

Discussion

Orbital exenteration was first described by Georg Bartisch in 1583, but it was popularized in the modern era by Arlt, Mouriaux and colleagues. Orbital exenteration was classified as subtotal, total and extended by Ben Simon [15]. Furthermore, Meyer and Zaoli further classified orbital exenteration intraoperatively, according to the extent of destruction of the surrounding bones as:

Type I: Palpebral skin and conjunctiva are spared;
Type II: Only the palpebral skin is spared and the eyeball and its appendages are removed with the conjunctiva;
Type III: Both eyelids are removed with orbital contents;
Type IV: The eyeball, eyelids, and appendages of the eye are removed with the involved bony structures [16, 17].

Periorbital skin cancers are more prevalent among the elderly. In our study, the mean age of the patients was 68.8 years (59–89 years old) and 65 % of the patients were male. According to the literature, periorbital skin cancers are most commonly located on the lower eyelid and the medial canthus [18–20], which is in correlation with our results (Table).

The main indication for exenteration in our patients was treatment of malignancy that was not amenable to local excision without compromising the eye. According to the literature, basal cell carcinomas constitute 80–90 % of all malignant tumors located on the eyelids, [18, 21, 22] and it is the most common reason for orbital exenteration [23, 24].

The most frequent indication for exenteration in our series was basal cell carcinoma as well, which accounted for 82.6 % of all tumors. All of the patients had recurrent tumors and they had previously undergone surgery for 3.8 times on average [3–8]. Five out of 26 patients had received radiotherapy for recurrent BCC before orbital exenteration; hence, four of these patients went under reconstruction with latissimus dorsi free flap. Superficial temporal artery (STA) forehead flap was used in the remaining one patient who had radiotherapy previously but the tissue on the forehead was spared from the radiation.

Squamous cell carcinoma is the second most common malignant neoplasm of the eyelids, accounting for 5–10 % of all eyelid malignancies [25]. However, a number of recent series have reported that it is the most prevalent tumor for which exenteration was performed [15, 26–28]. In our series, 17.4 % of the exenterations were performed for squamous cell carcinoma.

The aim of the operation is to achieve local control of the advanced disease and the reconstruction should include closure of defect and obliteration of the communication between the orbital cavity and the nasal cavity or the paranasal sinuses. Nevertheless, it should also allow for early detection of recurrences. The donor tissue to cover the defect is quite important especially in patients requiring postoperative radiotherapy; besides, it should satisfy aesthetic requirements [29]. For this reason, the reconstruction is a major challenge, particularly in elderly patients.

Many techniques have been described for reconstruction of the exenterated orbit. The first approach after excision of the tumor was to leave it for secondary healing followed by

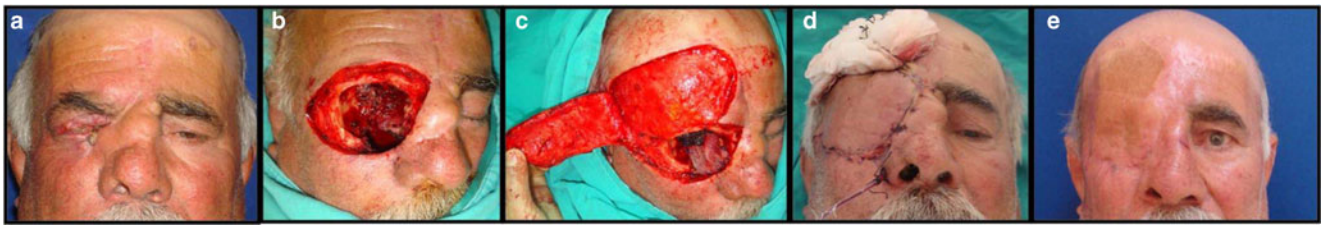

Fig. 3 Patient with recurrent basal cell carcinoma following extensive exenteration and right maxillectomy. Orbital floor reconstructed with prolene mesh followed by closure of the defect with STA flap

Fig. 4 Patient with recurrent basal cell carcinoma following exenteration and reconstruction using scalp flap

spontaneous granulation and epithelisation [15]. Spontaneous granulation provides a simple technique but its main disadvantage is that healing takes several months that may cause a delay in radiotherapy, and there is a great risk of infection that can affect the final cosmetic result. [30].

The next approach is the use of a split thickness skin graft [29, 31]. Skin grafting of the exenterated orbit results in more rapid healing than with spontaneous granulation, but the risk of graft failure is high when the periostium has been removed or if the patient had received preoperative radiotherapy [26]. However, skin grafting enables an open cavity reconstruction,

Fig. 5 Patient with an extensive basal cell carcinoma. Preoperative view, following exenteration, temporal bone excision and reconstruction with free latissimus dorsi flap

therefore allowing the patient to use prosthesis [26]. Yet, in our clinical series, split thickness skin graft was used for donor site deformity on the frontal region rather than for closing the primary defect.

Many authors have suggested that locoregional flaps can be used for the reconstruction of the orbital region such as the cheek V-Y advancement flap, the galeal flap [8, 32, 33], the temporal muscle flap [8, 26, 34, 35], the temporoparietal fascial flap [7, 26], the prefabricated temporal island flap which is Altindas-2 procedure [36], the cervicofacial flaps [37], the forehead flap [38, 39], and the scalp flap and frontal flaps [30, 40–44]. The dermis–fat graft from the abdominal wall was also used to fill the cavity [11]. In our study, the defect was closed with a superficial temporal artery-based forehead flap in 17 patients (73.96 %) and the scalp flap in 3 patients (13.04 %). We think that the use of superficial temporal artery-based forehead flap has many advantages. First, it is a relatively simple, less time-consuming, safe procedure and the hospitalization of the patients was shorter when compared to a more complex flap procedure. Postoperative radiation treatment can be well tolerated. Thickness of the forehead tissue provides open cavity reconstruction of the orbital socket. Open cavity allows for more secure fit of the prosthesis as offered by Hanasono et al. [26]. Unfortunately, only one of our patients had used spectacle-mounted prosthesis for a very short period, after then he preferred to wear a patch.

Reconstructive options with a free tissue transfer include the rectus abdominis [26, 45], latissimus dorsi [46], radial forearm [26, 47], lateral arm or anterolateral thigh flap [26]. Free flap reconstruction is the method of choice especially in cases where the orbital walls are also resected and almost the only method in case of exenteration with total maxillectomy [26]. However, all these free flap procedures are time consuming, they do not allow good accommodation of prosthetics, and have several complications although the rate of complications may not necessarily be significantly higher compared to skin grafting as shown by Hanasono et al. For these reasons, free flap reconstruction may not be suitable for elderly patients with a high ASA grade and if the patient does not have any concern about using prosthesis. Free latissimus dorsi flap was used for four patients in our series. It is very effective when the defect in the orbital walls is too large or radiotherapy had been used preoperatively. Adjuvant chemotherapy and plaque radiotherapy may improve the surgical cure rates for these aggressive neoplasms [48]. Adjuvant radiotherapy was applied for two of our patients who had evidence of tumor cells at the surgical margins and these patients did not develop local recurrence during the follow- up period.

However, the drawback of this study that the small number of patients in each subgroup does not allow for statistical analysis to make a comparison between reconstructive techniques should be kept in mind. Therefore, these are solely our experience based on results.

Conclusion

Choice of a reconstructive technique depends on many factors such as the patient's age, donor–recipient site conditions, patient's comorbidities, the extent of the tumor, the patient's desire to wear prosthesis as well as the surgeon's personal experience especially regarding microvascular expertise. Besides, superficial temporal artery-based forehead flap provides a relatively simple solution for the reconstruction of an exenterated socket, considering that the population we are facing has significant comorbidities. The final outcome according to our limited experience is comparable to that of more complex flap procedures, providing an acceptable cosmetic result with minimal donor site morbidity, and short operating time.

Conflict of interest None.

References

1. Blitzer A, Lawson W, Meyers BR, Biller H (1980) Patient survival factors in paranasal sinus mucormycosis. Laryngoscope 90:635–648
2. Hargrove RN, Wesley RE, Klippenstein KA, Fleming JC, Haik BG (2006) Indications for orbital exenteration in mucormycosis. Ophthal Plast Reconstr Surg 22:286–291
3. Goldberg RA, Kim JW, Shorr N (2003) Orbital exenteration: results of an individualized approach. Ophthal Plast Reconstr Surg 19(3):229–236
4. Rahman I, Cook AE, Leatherbarrow B (2005) Orbital exenteration: a 13-year Manchester experience. Br J Ophthalmol 89:1335–1340
5. Taylor A, Roberts F, Kemp EG (2006) Orbital exenteration—a retrospective study over an 11-year period analyzing all cases from a single unit. Orbit 25:185–193
6. Tyers AG (2006) Orbital exenteration for invasive skin tumours. Eye 20:1165–1170
7. Bartley GB, Garrity JA, Waller RR et al (1989) Orbital exenteration at the Mayo clinic 1967–1986. Ophthalmology 96:468–471
8. Menon NG, Girotto JA, Goldberg NH, Silverman RP (2003) Orbital reconstruction after exenteration: use of transorbital temporal muscle flap. Ann Plast Surg 50:38–42
9. Cuesta-Gil M, Concejo C, Acero J, Navarro-Vila C, Ochandiano S (2004) Repair of large orbito-cutaneous defects by combining two classical flaps. J Craniomaxillofac Surg 32:21–27
10. Wax M, Burkey BB, Bascom D, Rosenthal EL (2003) The role of free tissue transfer in the reconstruction of massive neglected skin cancers of the head and neck. Arch Facial Plast Surg 5:479–482
11. Uusitalo M, Ibarra M, Fulton L et al (2001) Reconstruction with rectus abdominis myocutaneous free flap after orbital exenteration in children. Arch Ophthalmol 119:1705–1709
12. Bartley G, Kasperbauer JL (2002) Use of a flap of extraocular muscle and fat during subtotal exenteration to repair bony orbital defects. Am J Ophthalmol 134:787–788
13. Lee H, Hong JP, Kim KT, Chung YK, Tark KC, Bong JP (1999) Orbital floor and infraorbital rim reconstruction after total maxillectomy using a vascularized calvarial bone flap. Plast Reconstr Surg 104:646–653
14. Lim N, Mulhern MG, Joshi N, Waterhouse N, Peterson D, Coghlan B (2002) The use of autologous autoclaved bone in orbital reconstruction after exenteration for invasive cutaneous carcinoma. Orbit 21:181–187
15. Ben Simon GJ, Schwarcz RM, Douglas R, Fiaschetti D, Mccann JD, Goldberg RA (2005) Orbital exenteration: one size does not fit all. Am J Ophthalmol 139:11–17
16. Radici M, Bicciolo G, Palma O, Bozza F (1996) Il massiccio facciale. In: Decampora E, Marzetti F (eds) La chirurgia oncologica della testa e del collo. Pacini editore, Pisa, pp 345–381
17. Zaoli G, Motta G (1978) La chirurgia ricostruttiva nel cancro della testa e del collo. Piccin editore, Padova
18. Guerra AS, Barbosa R, Choupina M et al (2011) Orbital exenteration for eyelid skin carcinoma. Eur J Plast Surg 34:239–243
19. Howard GR, Nerad JA, Carter KD et al (1992) Clinical characteristics associated with orbital invasion of cutaneous basal cell and squamous cell tumours of the eyelid. Am J Ophthalmol 113:123–133
20. Salomon J, Bieniek A, Baran E et al (2004) Basal cell carcinoma on the eyelids: own experience. Dermatol Surg 30:257–263
21. Amoaku WMK, Bagegni A, Logan WC et al (1990) Orbital infiltration by eyelid skin carcinoma. Int Ophthalmol 14:285–294
22. Glover AT, Grove AS (1989) Orbital invasion by malignant eyelid tumours. Ophthal Plast Reconstr Surg 5:1–12
23. Simons JN, Robinson DW, Masters FW (1966) Malignant tumours of the orbit and periorbital structures treated by exenteration. Plast Reconstr Surg 37:100–104
24. De Conciliis C, Bonavolonta G (1987) Incidence and treatment of dural exposure and CSF leak during orbital exenteration. Ophthal Plast Reconstr Surg 3:61–63
25. Donaldson MJ, Sullivan TJ, Whitehead KJ et al (2002) Squamous cell carcinoma of the eyelids. Br J Ophthalmol 86:1161–1165
26. Hanasono MM, Lee JC, Yang JS et al (2009) An algorithmic approach to reconstructive surgery and prosthetic rehabilitation after orbital exenteration. Plast Reconstr Surg 123:98
27. Kayr A, Khattri M, Jaiswal V (2012) Pattern of orbital exenteration at a tertiary eye care centre in North India. Nepal J Ophthalmol 4 (7):64–67
28. Pushker N, Kashyap S, Blalsubramanya R et al (2004) Pattern of orbital exenteration in a tertiary eye care centre in India. Clin Experiment Ophthalmol 32:51–54
29. Shields JA, Shields CL, Demirci H et al (2001) Experience with eyelid sparing orbital exenteration: the 2000 Tullos O. Coston Lecture. Ophthal Plast Reconstr Surg 17(5):355–361
30. Putterman AM (1986) Orbital exenteration with spontaneous granulation. Arch Ophthalmol 104:139–140
31. Frezzotti R, Bonanni R, Nuti A, Polito E (1992) Radical orbital resections. Adv Ophthal Plast Reconstr Surg 9:175–192
32. Mohr C, Esser J (1997) Orbital exenteration: surgical and reconstructive strategies. Graefes Arch Clin Exp Ophthalmol 235(5):288–295
33. Gunalp I, Gunduz K, Duruk K (1995) Orbital exenteration: a review of 429 cases. Int Ophthalmol 19(3):177–184
34. Rathbun J, Beard C, Quickert MH (1971) Evaluation of 48 cases of orbital exenteration. Am J Ophthalmol 30:191–199
35. Menderes A, Yilmaz M, Vayvada H et al (2002) Reverse temporalis muscle flap for the reconstruction of orbital exenteration defects. Ann Plast Surg 48:521–527
36. Altindas M, Yucel A, Ozturk G et al (2010) The prefabricated temporal island flap for eyelid and eye socket reconstruction in otal orbital exenteration patients. Ann Plas Surg 65:177–182
37. Mercer DM (1988) The cervicofacial flap. Br J Plast Surg 41:470–474
38. Kovacevic PT, Visnjic MM, Kovacevic TT et al (2009) Extended orbital exenteration in the treatment of advanced periocular skin cancer with primary reconstruction with a galeacutaneous flap. Scand J Plast Surg Hand Surg 43:325–329
39. Dortzbach RK, Hawes MJ (1981) Midline forehead flap in reconstructive procedures of the eyelids and exenterated socket. Ophthalmic Surg 12:257–268

40. Ohtsuka H (1988) Eye socket and eyelid reconstruction using combined island frontal flap and retroauricular island flap: a preliminary report. Ann Plast Surg 20:244–248
41. Price DL, Sherris DA, Bartley GB et al (2004) Forehead flap periorbital reconstruction. Arch Facial Plast Surg 6:222–227
42. Mauriello JA, Han KH, Wolfe R (1985) Use of autogenous splitthickness dermal graft for reconstruction after subtotal exenteration. Am J Ophthalmol 100:465–467
43. Shore JW, Burks R, Leone CR et al (1986) Dermis fat graft for orbital reconstruction after subtotal exenteration. Am J Ophthalmol 102:228–236
44. Cook BE Jr, Bartley GB (1999) Epidemiologic characteristics and clinical course of patients with malignant eyelid tumours in an incidence cohort in Olmsted County, Minnesota. Ophthalmology 106:746–750
45. Donahue PJ, Liston SL, Falconer DP et al (1989) Reconstruction of orbital exenteration cavities. The use of the latissimus dorsi myocutaneous free flap. Arch Ophthalmol 107:1681–1683
46. Tahara S, Susuki T (1989) Eye socket reconstruction with free radial forearm flap. Ann Plast Surg 23:112–116
47. Meldrum ML, Tse DT, Benedetto P (1998) Neoadjuvant intracarotid chemotherapy for the treatment of advanced adenoid cystic carcinoma of the lacrimal gland. Arch Ophthalmol 1163:315–321
48. Shields JA, Shields CL, Freire JE et al (2003) Plaque radiotherapy for selected orbital malignancies: preliminary observations: the 2002 Montgomery Lecture, part 2. Ophthal Plast Reconstr Surg 19:91–95