Journal of Plastic, Reconstructive & Aesthetic Surgery (2012) **65**, 578—583

The reading man flap for closure of large meningomyelocele defects☆

Mehmet Mutaf*, Metin Temel, Ertan Günal

University of Gaziantep, Faculty of Medicine, Department of Plastic, Reconstructive and Aesthetic Surgery, Gaziantep, Turkey

Received 8 August 2011; accepted 6 October 2011

KEYWORDS
Meningomyelocele;
Lumbosacral region;
Local flap;
The unequal Z-plasty;
Reading man procedure

Summary *Background:* Closure of the skin defect in myelomeningocele repair is an essential step that determines the quality of the surgical result. In large myelomeningoceles, however, adequate skin coverage may not be accomplished by direct closure or skin undermining. In such cases, the skin defect is best repaired using flaps. The aim of this study is to evaluate the reading man procedure for closure of large meningomyelocele defect.
Methods: In this procedure, after neurosurgical repair and closure of the placode, the defect surgically becomes a circle in shape. Then, the circular defect is closed by transposition of two skin flaps designed in an unequal Z-plasty manner. Over 5 years, the reading man procedure was used for closure of large meningomyelocele defects in seven patients (four females and three males), aged between 1.5 and 6 months. The defect size was 10.5 × 7.25 cm (8.5 × 5.3 and 12.6 × 9.5 cm) on average. The localisation of the lesions was thoracolumbar in two patients and lumbosacral in five patients.
Results: In all patients, a successful tension-free one-stage closure was obtained without dog-ear formation. Except for one patient with minimal tip necrosis, healing was uneventful without any complications. There was no patient with late breakdown of the wound during 1.5 years (8 months—4 years) of mean follow-up.
Conclusions: The reading man procedure enables the surgeon to achieve a tension-free defect closure of considerably large meningomyeleocele defects. Using two well-vascularised fascio-cutaneous flaps, it provides a durable coverage and soft tissue padding over the neural tissues with no suture seam at midline. With these advantages, the Reading Man Procedure seems to be a useful and safe alternative for closure of large meningomyelocele defects.

☆ This study was presented at the XXXIIth Annual Congress of Turkish Society of Plastic, Reconstructive and Aesthetic Surgery, in Trabzon, Turkey, 15—19 September 2010.

* Corresponding author. Tel.: +90 5327284818.
E-mail address: dr.mutaf@gmail.com (M. Mutaf).

1748-6815/$ - see front matter
doi:10.1016/j.bjps.2011.10.010

Although the incidence is declining as a result of prenatal screening for neural-tube defects, a meningomyelocele still remains a common congenital anomaly seen in approximately 1 in 1000 live births.[1] It is characterised by insertion of neural elements into a pouch floored by meninx through a vertebral defect. The lumbosacral area is the site of approximately three-quarters of cases. This anomaly should be surgically repaired immediately after birth to prevent infection and leakage of cerebrospinal fluid (CSF), besides protecting the neural elements.[2] Although many techniques have been described for the treatment of this congenital anomaly, closure of large meningomyelocele defects (MMDs) is still a great challenge in reconstructive surgery.[3–9]

In this article, the authors present 5 years of clinical experience with the use of the reading man procedure (RMP) as a new alternative in surgical closure of large MMDs.

Surgical technique

After neural repair is achieved by a neurosurgeon, the design of the reading man flap is outlined on the patient. In the RMP, two skin flaps designed in an unequal Z-plasty manner are used (45°/60°). During surgical planning, the position of the unequal Z-plasty should be decided carefully to avoid placement of the suture lines over the midline where the neural-tube repair is needed (Figure. 1(a)). Once its direction is decided, the central limb of the unequal Z-plasty is drawn as an imaginary tangential line passing through the margin of the circular MMD. The length of the central limb of the Z-plasty is designed to be 50% longer than the diameter of the circular defect. Beginning from the free end of this line, another imaginary line is drawn as the first lateral limb with an angle of 60°. Then, the second lateral limb of the unequal Z is drawn with an angle of 45°.

By completion of this surgical design, two skin flaps (f1 and f2) are obtained (Figure 1(b)). The flaps are elevated through the supramuscular plane as fasciocutaneous flaps, taking care to preserve the perforator vessels at their bases. Once the flaps are elevated, f1 is moved to the defect area and f2 is transposed to cover the donor site of f1 (Figure 1(c)) A suction drain is placed beneath the skin flaps as required and the skin closure is done in layers, using 3/0–4/0 Vicryl for the subcutaneous layer and 5/0 polypropylene for the skin. Suction drains are kept in place for 4–6 days after surgery (Figure. 1(d) and (e)). Postoperatively, infants are positioned prone for 7 days and during this time an antibiotic is given parenterally.

Patients and methods

Over 5 years, this new technique was used for closure of large MMDs in seven patients (four females and three males). The mean age of the infants was 1.5–6 months, and the dimensions of MMD were 10.5 × 7.25 cm (from 8.5 × 5.3 to 12.6 × 9.5 cm) on average. The localisation of meningomyelocele was thoracolumbar in two patients and lumbosacral in five patients (Table 1). The mean follow-up was 1.5 years (8 months–4 years). Except one, all patients had flaccid paralysis of both lower extremities and hydrocephalus with frontal bossing, and their hydrocephalus was treated with shunt placement during the same operation by neurosurgeons from the same institute. There were no other additional anomalies.

Results

A successful tension-free closure of the defect was obtained in all patients with no suture line over the neural repair. The operation time in all patients was between 30 and 40 min. All patients tolerated the procedure without blood transfusion and without perioperative complications. Except for one patient with minor flap tip necrosis who underwent secondary healing, all patients healed uneventfully without cerebral fluid leakage. The patients were discharged within 6–12 days. After suture removal done at 10–12 days postoperatively, they were scheduled for follow-up visits every 2 weeks for evaluation of our late-term results.

A 1.5 months of mean follow-up revealed a durable coverage in all patients. There was no patient with late breakthrough of the wound. No patient required secondary surgery in this clinical series. However, two patients (cases #4 and #5) died because of pulmonary infection at 6 months and 1 month after surgery, respectively.

Discussion

Up until today, a number of surgical techniques have been suggested to achieve a tension-free skin closure and stable soft tissue padding with minimal blood loss and short operative time in closure of MMD. Primary closure is possible with undermining of the wound margins in almost 75% of cases. However, the remaining 25% of the patients with large defects (>5 cm in diameter) require a more complex procedure.[4,6,10,11]

Skin grafting of a MMD is a simple procedure with low immediate complication rate,[3,12] but late problems of gibbus deformity, ulceration or infection are not uncommon and may necessitate secondary surgical interventions.[12,13] Thus, several authors prefer a flap closure to skin grafting. Several skin flap procedures have been described for closure of MMDs including classical transposition[14] and rotation flaps,[8,10,11] the V–Y advancement flaps,[4,15,16] the bipedicled flap,[17] the Limberg flap[18,19,20] and bilobed flap.[5]

Although they are useful and easy procedures, the transposition and rotation flaps share a common major drawback as their donor sites often need to be covered with a split-thickness skin graft. This means an additional donor wound with a prolonged operational time, further blood-loss and an ugly scar at late term. The V–Y advancement flaps have been reported as another useful alternative in reconstruction of the MMDs.[5,9] However, suture lines overlie the neural repair and make CSF leakage and infection more likely.[19] More recently, Akan et al.[16] using a modified bilateral V–Y advancement flap in 10 patients reported good results with no complications. In spite of their impressive results obtained with this modification, we believe that use of the V–Y advancement flaps in

Figure 1 Case 1: a 2-month-old female newborn with a large meningomyelocele on lumbosacral region is referred to our clinic. (A) After neurosurgical repair, intraoperative view showing the defect measured as 8.2 cm × 6 cm in diameter. During surgical planning, position of the unequal Z-plasty mustshould be decided carefully to avoid the placement of the suture lines over the midline where the neural-tube repair is existed. (B) 2 skin flaps (f1 and f2) are elevated through the supramuscular plane as fasciocutaneous flaps, taking care to preserve the perforator vessels at their bases. (C) Once the flaps are elevated, the f1 is transposed to the defect area and the f2 is moved to cover the donor site of f1. (D) The skin closure is done in layers, using 3/0—4/0 Vicryl for subcutaneous layer and 5—0 polypropylene for the skin. (E) This procedure provides a durable coverage and soft tissue padding over the neural tissues at 2 months after surgery.

Table 1 Clinical data.

Patient No./sex	Age (months)	Defect size (cm)	Defect localisations	Early complication	Neurologic status
1/F	2	8.6 × 6	Lumbosacral	None	Paraplegic
2/M	1.5	8.5 × 5.3	Thoracolumbar	Minor Tip Necrozis	Paraplegic
3/F	2	8 × 6.5	Lumbosacral	None	Normal
4/F	6	12.6 × 9.5	Lumbosacral	None	Paraplegic
5/M	4	12.3 × 7.5	Thoracolumbar	None	Paraplegic
6/F	5	12.5 × 8.5	Lumbosacral	None	Paraplegic
7/M	3	11.5 × 7.5	Lumbosacral	None	Paraplegic

reconstruction of MMDs should be limited to small and moderate defects. Otherwise, extensive undermining is needed to provide further flap mobility that may damage perforator vessels supplying the skin. The double Z-rhomboid flap procedure has been reported by Cruz et al.[18] as another alternative for closure of MMDss. However, it resulted in unnecessarily extensive scarring, and suture lines overlie the neural repair, too.

The Limberg flap has been one of the most popular procedures in reconstruction of MMDs.[19,20] Although it seems to be useful for small and medium defects, the Limberg flap often fails to provide a tension-free closure for large MMDs.

The use of a musculocutaneous flap has been reported as a superior alternative to surgical repair of large myleomeningoceles. Since Desperez et al.[21] reported the use of a latissimus dorsi myocutaneous flap in the repair of MMDs in 1971 there have been several reports of the use of various musculocutaneous flaps for closure of MMDs.[9,15,16,,22–25] Although the initial experience with these flaps was quite encouraging, the use of the musculocutaneous flaps for coverage of MMDs is associated with high complication rates.[26] In recent studies, their use in neonates with myelomeningocoeles has been criticised because of two important drawbacks: increased blood loss and longer operating time. Disruption of the latissimus muscle integrity also carries the potential risk of functional loss in a potentially paraplegic wheelchair-bound patient who will be largely dependent on this muscle for ambulation. In addition, these patients are quite likely to have pressure sores and may need additional surgery in the late term. Considering these factors, preservation of the muscle flap options for long-term coverage problems seems to be a more logical strategy in these patients.

As a reflection of their increasing popularity in reconstructive surgery, the perforatory flaps have been suggested as a new approach for the repair of MMDs in recent clinical studies. Duffy et al.[7] reported the use of the superior gluteal artery perforator flap for closure of lumbosacral MMDs in 2004. More recently, Işık et al.[27]reported the use of the dorsal intercostal artery perforator flap for the repair of thoracal MMDs. Although these both studies are valuable flap options in the treatment of this challenging reconstructive problem, the use of the perforatory flap seems to be useful only for the small- and medium-sized MMDs. In patients with large MMDs, their use may bring additional donor site problems, such as requirement of the skin graft, which means additional morbidity and an ugly scar in the long term. Moreover, these flaps require a careful and time-consuming dissection technique. This seems to be another crucial factor that can restrict their use in neonates in whom a short operative time is desired.

Compared with the musculocutaneous and perforator flaps, dissection of the local skin flaps is much easier to apply and requires lesser operative time and blood loss. As confirmed with our results, they have been reported to provide a well-vascularised and durable coverage with no wound break in long term. Moreover, they do not cause any functional deficits and the muscles of the gluteal region and back region can be spared for later reconstruction.[28] In light of this information, we believe that the use of local skin flaps is the most suitable solution in reconstruction of the neonates with myelomeningoceles.

In this study, we described the use of a new skin flap procedure, namely the Reading man RM, for closure of large MMDs. The RMP was first described by Dr. Mutaf in 2005[29] and published in the English literature in 2008. [30] In a clinical series of 17 patients, he reported the use of the RMP for reconstruction of various skin defects located in different anatomical areas including the preauricular and malar regions, torso and the lower extremities. This is the first clinical series of the use of the RMP for closure of MMDs.

In recent anatomical studies, fasciocutaneous flaps, elevated around the paraspinal area for repairing of the MMDs, have been demonstrated to be safe in terms of vascular supply.[31] However, Ramirez et al.[6] reported that skin flaps, such as the bipedicled flap, local transposition flaps and Limberg-type flaps, involve a 20% risk of necrosis since they fail to provide a tensionless closure and require excessive undermining. As a matter of fact, the success of a local flap procedure is much more related with surgical planning. These previously described that surgical procedures similarly attempt to achieve defect closure by the use of a single flap without any special manoeuvre to provide extra tissue relaxation. As another common feature of these techniques, the entire tissue used for defect closure is borrowed from only one direction and the donor site is closed with either undermining or stretching of the wound margins or a skin graft. In the RMP, two fasciocutaneous flaps obtained with an unequal Z-plasty design are used. Besides, it provides a considerable amount of extra tissue relaxation, and the use of a Z-plasty design enables the surgeon to borrow tissue from all directions. One of the flaps is used for defect closure and the other one is used for closure of the donor site of the primary flap without wide undermining of wound margins (Figure 1). Using the advantage of extra tissue relaxation provided by an unequal Z-plasty, the RMP remarkably reduces the tension at closure lines that seems to be a critical factor to decrease the risk of wound healing problems. Nevertheless, except for one early patient with tip necrosis who healed spontaneously, there was no patient with flap necrosis and other wound healing problems in our series.

Various alternative markings of the RMP can be used for closure of MMDs as given in Figure 2. Considering the size, shape and the location of the MMD, the surgeon must choose the most suitable design for the individual requirements of each patient. Especially, the position of Z-plasty should be decided very carefully as the final suture lines should not be placed on the midline, over the neural repair. This issue has been reported as an important factor to avoid CSF leakage and fistulas in early and later terms.[5,19] To ensure this in the RMP, the central limb of the Z-plasty should be positioned oblique or perpendicular to the midline.

In comparison with previously reported methods, the RMP offers several advantages in closure of MMDs: (1) no skin graft is needed; (2) no muscle is sacrificed; (3) it is easy to apply with less blood loss and a shorter operative time; (4) it is a safe procedure, avoiding suture seams at midline as a critical achievement to minimise the risk of CSF leakage and infection; and (5) using an unequal Z-plasty, it provides extra tissue relaxation and enables the surgeon to achieve a tension-free one-stage closure of considerably large MMDs without risk of wound dehiscence. Based on the

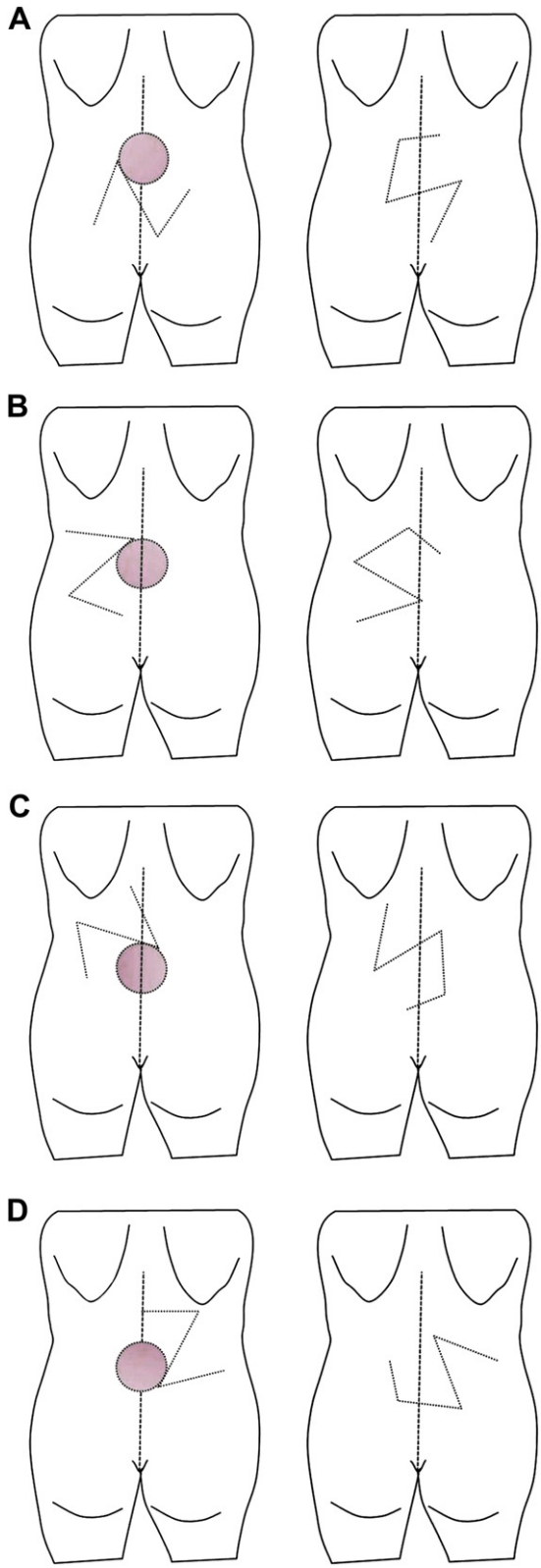

Figure 2 Illustration showing various designs of the RMP and postoperative scars of each design.

results of this clinical study, the authors believe that the RMP is a potentially useful option that should be considered when closing a large MMD.

Conflict of interest

None declared.

Funding

None declared.

Acknowledgements

None of the authors has a financial interest in any of the products, devices or drugs mentioned in this article.

References

1. Reigel DH. Myelomeningocele. In: Cheek WR, editor. *Atlas of pediatric neurosurgery*. 1st ed. Philadelphia: W.B. Saunders; 1996. p. 1—9.
2. Cohen AR, Robinson S. Early management of myelomeningocele. In: McLone DG, editor. *pediatric neurosurgery: surgery of the developing nervous system*. Philadelphia, PA: Saunders; 2001. p. 241—59.
3. Luce EA, Stigers S, Vandenbrink KD, et al. Split-thickness skin grafting of the myelomeningocele defect: a subset at risk for late ulceration. *Plast Reconstr Surg* 1991;**87**:116—21.
4. Ulusoy MG, Kocer U, Sungur N, et al. Closure of meningomyelocele defects with bilateral modified V-Y advancement flaps. *Ann Plast Surg* 2005;**54**:640—4.
5. Lapid O, Rosenberg L, Cohen A. Meningomyelocele reconstruction with bilobed flaps. *Br J Plast Surg* 2001;**54**:570—2.
6. Ramirez OM, Ramasastry SS, Granick MS, et al. A new surgical approach to closure of large lumbosacral meningomyelocele defects. *Plast Reconstr Surg* 1987;**80**:799—809.
7. Duffy Jr FJ, Weprin BE, Swift DM. A new approach to closure of large lumbosacral myelomeningoceles: the superior gluteal artery perforator flap. *Plast Reconstr Surg* 2004;**53**:305—10.
8. Atik B, Tan O, Mutaf M, et al. Skin perforators of back region: anatomical study and clinical applications. *Ann Plast Surg* 2008;**60**:70—5.
9. Hayashi A, Maruyama Y. Bilateral latissimus dorsi V—Y musculocutaneous flap for closure of a large meningomyelocele. *PlastReconstr Surg* 1991;**88**:520.
10. Davies D, Adendorff DJ. A large rotation flap raised across the midline to close lumbosacral meningomyeloceles. *Br J Plast Surg* 1977;**30**:166—8.
11. Patterson TJ. The use of rotation flaps following excision of lumbar myelomeningoceles: an aid for the closure of large defects. *Br J Surg* 1959;**46**:606—8.
12. Luce EA, Walsh J. Wound closure of the myelomeningocele defect. *Plast Reconstr Surg* 1985;**75**:389—93.
13. Davila FB, Luce EA. Current considerations for myelomeningocele repair. *J Craniofac Surg* 2000;**11**:500.
14. Bajaj PS, Welsh F, Shadid EA. Versatility of lumbar transposition flaps in the closure of meningomyelocele skin defects. *Ann Plast Surg* 1979;**2**:103—8.
15. Sarifakioglu N, Bingul F, Terzioglu A, et al. Bilateral split latissimus dorsi V-Y flaps for closure of large thoracolumbar meningomyelocele defects. *Br J Plast Surg*. 2003;**56**:303—6.
16. Akan IM, Ulusoy MG, Bilen BT, et al. Modified bilateral advancement flap: the slide-in flap. *Ann Plast Surg* 1999;**42**: 545—8.
17. Mangels KJ, Tulipan N, Bruner JP, et al. Use of bipedicular advancement flaps for intrauterine closure of myeloschisis. *Pediatr Neurosurg* 2000;**32**:52—6.

18. Cruz NI, Ariyan S, Duncan CC, et al. Repair of lumbosacral myelomeningoceles with double Z-rhomboid flaps. Technical note. *J Neurosurg* 1983;**59**:714—7.
19. Campobasso P, Pesce C, Costa L, et al. The use of Limberg skin flap for closure of large lumbosacral myelomeningoceles. *Pediatr Surg Int* 2004;**20**:144—7.
20. Ohtsuka H, Shioya N, Yada K. Modified Limberg flap for lumbosacral meningomyelocele defects. *Ann Plast Surg* 1979; **3**:114—7.
21. Desperez JD, Kiehn CL, Eckstein W. Closure of large myelomeningocele defects by composite skin-muscle flaps. *Plastic Reconstr Surg* 1971;**47**:234—8.
22. Meuli-Simmen C, Meuli M. Latissimus dorsi flap procedures to cover myelomeningocele in utero: a feasibility study in human fetuses. *J Pediatr Surg* 1997;**32**:1154.
23. McCraw JB, Penix JO, Freeman BG, et al. Soft-tissue repair of myelomeningocele defects using bilateral latissimus dorsi and trapezius musculocutaneous flaps. *Ann Plast Surg* 1987;**18**: 147—55.
24. Moore TS, Dreyer TM, Bevin AG. Closure of large spina bifida cystica defects with bilateral bipedicled musculocutaneous flaps. *Plast Reconstr Surg* 1984;**73**:288—92.
25. McCraw JB, Penix JO, Baker JW. Repair of major defects of the chest wall and spine with the latissimus dorsi myocutaneous flap. *Plast Reconstr Surg* 1978;**62**:197—206.
26. Zide BM. Spina bifida. In: McCarthy JG, editor. *Plastic surgery*. Philadelphia: Saunders; 1990. p. 3780—90.
27. Isik D, Tekes L, Eseoglu M, Isik Y, Bilici S, Atik B. Closure of large myelomeningocele defects using dorsal intercostal artery perforator flap. *Ann Plas Surg* 2010.
28. Mutaf M, Bekerecioğlu M, Erkutlu I, Bulut Ö. A new technique for closure of large meningomyelocele defects. *Ann Plast Surg* 2007;**59**(5):538—43.
29. Mutaf M, Sunay M, Bulut Ö, et al. Reading Man procedure. Oral presentation at: the 27th Turkish National Congress of Plastic, Reconstructive and Aesthetic Surgery, Konya, Turkey; September 14—17, 2005.
30. Mutaf M, Sunay M, Bulut Ö. The "reading man" procedure a new technique for the closure of circular skin defects. *Ann Plast Surg* 2008;**60**:420—5.
31. Iacobucci JJ, Marks MW, Argenta LC. Anatomic studies and clinical experience with fasciocutaneous flap closure of large myelomeningoceles. *Plast Reconstr Surg* 1996;**97**:1400—8. Discussion 1409—1410.