Reconstruction of Congenital Isolated Alar Defect Using Mutaf Triangular Closure Technique in Pediatric Patients

Metin Temel, MD, Ertan Gunal, MD,† and Serif Samil Kahraman, MD‡*

Abstract: Congenital isolated alar defects are extremely rare, occurring in approximately 1 in 20,000 to 40,000 live births. The patients are presented here of 2 pediatric patients operated on for congenital isolated alar defect. The reconstruction of congenital isolated alar defects was made in a 3-layered fashion. The skin defects were covered using the Mutaf triangular closure technique in which 2 cutaneous local flaps are designed in an unequal Z-plasty manner. Conchal cartilage graft was used between the skin and mucosal closure to replace the missing part of the lower lateral cartilage in these patients. The early results were promising in Patient 1, but sufficient improvement was detected in the alar cartilage postoperative follow-up period in Patient 2. Hence, this patient required revision 1 to 2 years postoperatively. This technique provides excellent aesthetic and functional results, except for this problem in Tessier 2 cleft patients. The use of the Stair step flap technique with Mutaf triangle closure technique achieved cosmetically and functionally excellent results in the reconstruction and repair of a large, irregular, narrow cleft, in the inadequate rotation of the lateral part of the lower lateral cartilage. However, because of this problem, evaluation of the long-term follow-up of patients is necessary.

Key Words: Conchal cartilage, isolated congenital alar defect, nasal anomalies, pediatric, tessier no. 2 facial clefts, unequal Z-plasty

(*J Craniofac Surg* 2016;00: 00–00)

The nose is the most prominent feature on the face, and therefore, defects of the nose may lead to both psychological and social distress, especially in children. Congenital isolated alar defects (CIAD) are uncommon and to date only 8 patients have been reported. There are several classification systems of craniofacial clefts, of which the Tessier classification is the most commonly used. According to the Tessier classification, facial clefts involving the nose are type 0, 1, 2, or 3 clefts.[1]

From the *Department of Plastic and Reconstructive Surgery at Mustafa Kemal University, School of Medicine, Hatay; †Department of Plastic and Reconstructive Surgery at SEV American Hospital, Gaziantep; and ‡Department of Otolaryngology at Mustafa Kemal University, School of Medicine, Hatay, Turkey.
Received November 16, 2015; final revision received February 16, 2016.
Accepted for publication March 10, 2016.
Address correspondence and reprint requests to Asst Prof Serif Samil Kahraman, MD, Department of Otolaryngology/Head and Neck Surgery at Mustafa Kemal University, School of Medicine, 31115 Hatay, Turkey; E-mail: drserifsamil@gmail.com
The authors report no conflicts of interest.

ISSN: 1049-2275
DOI: 10.1097/SCS.0000000000002657

The patients reported here had congenital isolated nasal lower lateral cartilage aplasia. Conchal cartilage graft was used between the skin and mucosal closure to replace the missing part of the lower lateral cartilage in both patients. The aim of this paper was to present the results of patients with CIAD covered using the Mutaf triangular closure technique.[2]

CLINICAL REPORT

Patient 1

A 7-year-old girl was admitted to our clinic with complaints of unaesthetic appearance of the nose and psychosocial distress. There was no history of infection, trauma, or surgery. There was no positive family history of congenital defects. The lip and palate were normally developed and the occlusion was normal. Complete congenital absence of the lower lateral cartilage was determined. The patient had severe external nasal valve dysfunction and a concavity of the alar vault, even in the resting position. The patient was diagnosed as a congenital isolated alar rim defect or Tessier Type 2. On examination, a full thickness defect of 1.4 cm × 1.8 cm was measured on the left nostril rim (Fig. 1A and B). The reconstruction of the defect was made in a 3-layered fashion. The skin defect was covered using the Mutaf triangular closure technique in which 2 cutaneous local flaps are designed in an unequal Z-plasty manner. Conchal cartilage graft was used between the skin and mucosal closure to replace the missing part of the lower lateral cartilage in this patient. The mucosal defect was closed with a full thickness skin graft taken from the ear (Fig. 2A–D). The flaps healed with no complications. At 6 months postoperatively, there was a cosmetically and functionally excellent result with almost symmetrical nostrils and minimal scar formation (Fig. 1C and D).

Patient 2

A 6-year-old boy was admitted to our clinic with complaints of unaesthetic appearance of the nose and psychosocial distress. There was no history of infection, trauma, or surgery. There was no positive family history. There was a dermoid cyst in the glabellar region extending from the nasal dorsum. The lip and palate were normally developed and the occlusion was normal. The patient had severe external nasal valve dysfunction and a concavity of the alar vault, even in the resting position. The patient was diagnosed as a congenital isolated alar rim defect or Tessier Type 2. On examination, a full thickness defect of 1.5 cm × 1.0 cm was measured on the right nostril rim. Right alar cartilage was located superiorly, and the defect continued linearly from the middle of the alar cartilage to the superior (Fig. 3A and B). The reconstruction of the defect was made in a 3-layered fashion. The skin defect was covered using the Mutaf triangular closure technique in which 2 cutaneous local flaps are designed in an unequal Z-plasty manner. The mucosal defect was covered using the reverse Mutaf triangular closure technique. Conchal cartilage graft was used between the skin and mucosal closure to replace the missing part of the lower lateral cartilage in this patient (Fig. 3C). At 8 weeks postoperatively, there was not enough rotation in the lateral part of lower lateral cartilage and there

FIGURE 1. A 7-year-old girl with a left-sided congenital isolated alar defect. Anterior and oblique views. Preoperative (A, B) and postoperative views (C, D).

was seen to be some cleft in the medial part of the lower lateral cartilage (Fig. 3D). The problem of rotation was overcome with a Stair-step flap and the cleft was repaired in the medial part of the lower lateral cartilage (Fig. 4A and B). A nasal splint was applied to the patient for 4 months. Thus, all the layers of the nose were created. The flaps healed with no complications after both operations. At 1 year after the second surgery, there was a cosmetically and functionally excellent result with almost symmetrical nostrils and minimal scar formation (Fig. 4C and D).

DISCUSSION

Congenital isolated alar defect manifests in various shapes and sizes. For example, this anomaly may be shaped as a simple linear defect or it could be large enough to include 1 side of the nose.[2]

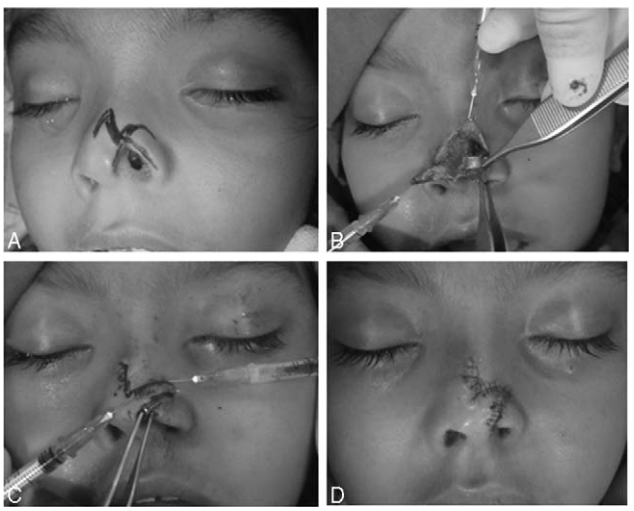

FIGURE 2. Surgical planning. Intraoperative views. Planning of flaps (A), reconstruction of the missing part of the alar cartilage with conchal cartilage (B), transposition of the flaps (C), view after suturation (D).

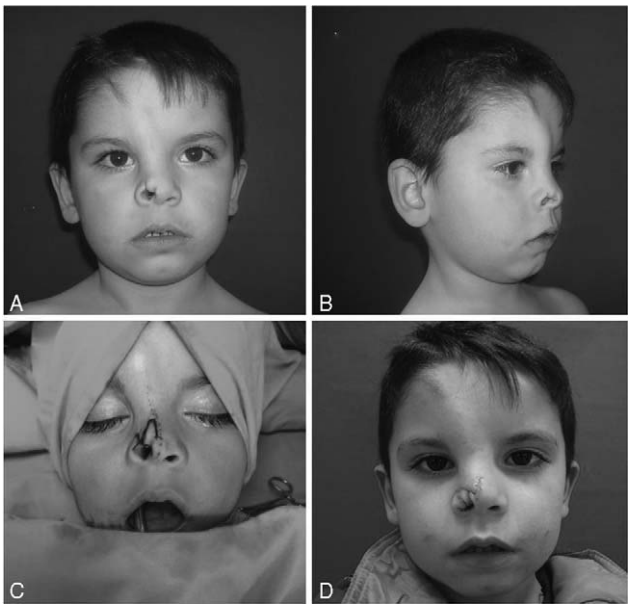

FIGURE 3. A 6-year-old boy with a right-sided congenital isolated alar defect. Anterior and oblique views. Preoperative (A, B) and intraoperative view, planning of flaps (C), early postoperative view (D).

Defects of the alar rim which include mucosa, cartilage, and skin are a reconstruction challenge for every plastic surgeon, due to the complex anatomy in this region. For minor defects, a composite graft harvested from the outer borders of the helix may be used.[3] Local flaps must be used for the closure of large defects as better aesthetic results are obtained.[2,4] The Mutaf triangle closure technique, which allows 3-layer repairs, can be considered an ideal method as there is similar skin color and inclusion of the same anatomical location. Using the Mutaf triangle closure technique for skin defects in these 2 patients, the mucosal defects were covered with full thickness skin grafts and conchal grafts were used for cartilage support.

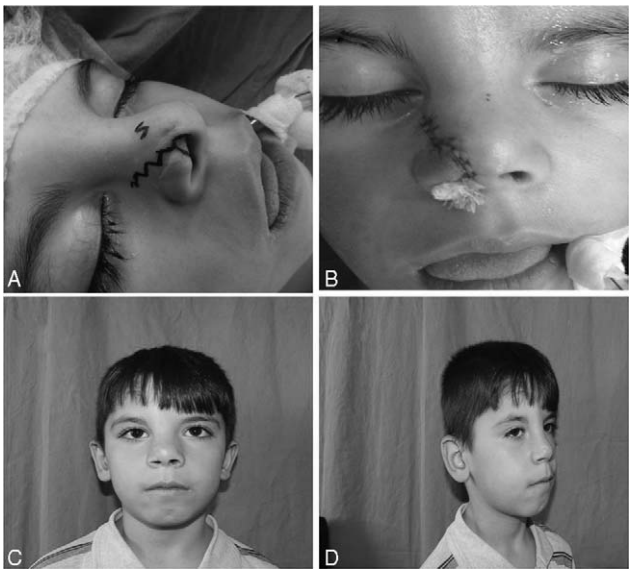

FIGURE 4. Second surgical planning. Intraoperative views. Planning of stair-step flaps (A), view after suturation (B), postoperative views (C and D).

When we look at the use of Mutaf triangular closure technique in the literature, this technique has been used for the closure of large meningomyelocele defects in 5 patients, aged between 2 days and 6 weeks.[5] This technique has been presented as a useful procedure for the closure of considerably large infraorbital defects with similar local tissue in 12 patients (7 men and 5 women), aged 28 to 83 years.[6] It has also been used to repair extensive sacrococcygeal hidradenitis suppurativa of the sacrococcygeal region as a new alternative in surgical treatment.[7]

Mutaf and Gunal[2] reported an adolescent patient with a wide CIAD on whom a new procedure, namely Mutaf triangular closure technique, was used for the reconstruction of the alar defect. Mutaf and Gunal[2] reported no scarring or irregularities in the alar cartilage due to complete development of the nose. They did not report its use for the reconstruction of CIAD in pediatric patients. The early results are promising in Patient 1, but we will have more information on the results related to the development of the patient's nose at a later date. In the postoperative follow-up period of Patient 2, insufficient improvement was detected in the alar cartilage postoperative. Hence, this patient required revision 1 to 2 years postoperatively. This technique provides excellent aesthetic and functional results, except for this problem in Tessier 2 cleft patients. With the use of the Stair step flap technique with the Mutaf triangle closure technique, a cosmetically and functionally excellent result was obtained in the reconstruction and repair of the large, irregular, narrow cleft, in the inadequate rotation of the lateral part of the lower lateral cartilage. However, because of this problem, evaluation of the long-term follow-up of patients is necessary.

For the reconstruction of the alar defect in the literature, a few such patients have been reported which were treated using a modified z-plasty described by Denonvillier.[8] Temiz et al[9] have reported the case of a patient with congenital complete absence of the lower lateral cartilage who treated using resected and reshaped nasal dorsal hump material. Gupta A and Gupta AK have reported a patient of congenital isolated unilateral alar cleft (Type 1 Tessier) which was reconstructed by a full thickness rotation advancement flap with best possible results.[10] There have no report pediatric patients in these articles. However, there has no report of the case of pediatric patient and there has no report that present the use of the Mutaf triangular closure technique for the reconstruction of the congenital isolated alar defect. The aim of this paper was to present triangular closure technique as a useful surgical procedure for the closure of CIAD in pediatric patients.

In patients of preschool age, surgery may be a psychosocial necessity to avoid becoming an object of derision by classmates and social exclusion. Children may become withdrawn and wish to spend more time at home, which may then result in psychosocial stress.

The reconstruction of the CIAD with Mutaf triangle closure technique and conchal cartilage graft in a pediatric patient may provide a cosmetically and functionally excellent result with almost symmetrical nostrils and minimal scar formation. In patients of preschool age, surgery may be necessary for psychosocial reasons, as delaying an operation until adulthood could create greater distress. This surgical procedure can be considered suitable for patients aged 7 years and above.

REFERENCES

1. Tessier P. Anatomical classification facial, cranio-facial and latero-facial clefts. *J Maxillofac Surg* 1976;4:69
2. Mutaf M, Gunal E. A new technique for reconstruction of a congenital isolated alar defect. *J Craniofac Surg* 2010;21:503
3. Jeffrey E. *Essentials of Plastic Surgery.* Missouri, St Louis: Quality Medical Publishing; 2007
4. Bilen BT, Kilinc H. A congenital isolated alar cleft. *J Craniofac Surg* 2006;17:602
5. Mutaf M, Bekerecioglu M, Erkutlu I, et al. A new technique for closure of large meningomyelocele defects. *Ann Plast Surg* 2007;59:538–543
6. Mutaf M, Gunal E, Temel M. A new technique for closure of infraorbital defects. *Ann Plast Surg* 2011;67:600–605
7. Mutaf M, Gunal E, Berberoglu O, et al. Surgical treatment of extensive sacrococcygeal hidradenitis suppurativa with triangular closure technique. *Ann Plast Surg* 2014;73:583–587
8. Novaković M, Baralić I, Stepić N, et al. Denonvilliers' advancement flap in congenital alar rim defects correction. *Vojnosanit Pregl* 2009;66:403–406
9. Temiz G, Yesiloglu N, Sarici M, et al. Congenital isolated aplasia of lower lateral cartilage and reconstruction using dorsal hump material. *J Craniofac Surg* 2014;25:e411–e413
10. Gupta A, Gupta AK. Rotation advancement flap for isolated congenital alar rim defect: an effortless paradigm? *Int J Pediatr Otorhinolaryngol* 2013;77:144–146