A New Technique for Total Reconstruction of the Lower Lid

Mehmet Mutaf, MD, and Metin Temel, MD†*

Background: Although several methods have been described for total lower eyelid reconstruction, it remains as a major challenge in reconstructive surgery. Here, we present a new technique, the Mutaf unequal Z-plasty procedure for reconstruction of defects of the lower eyelid.

Methods: In this technique, 2 skin flaps designed in an unequal Z-plasty manner are used to provide skin coverage. Except for 2 patients whose additional upper eyelid defects were closed with Fricke flap, all patients were reconstructed with Mutaf unequal Z-plasty procedure. The conjunctival and tarsal defects are reconstructed with composite chondrocutaneous from the ear, mucochondral grafts, harvested from the nasal septum. In over 12 years, this new technique was used in 24 patients, 13 men and 11 women, with total and subtotal lower eyelid defects that resulted from excision of basal cell carcinomas. The age range of the patients was between 45 and 72 years.

Results: There was no complication such as ocular irritation or postoperative epiphora because of ectropion or entropion; all patients healed uneventfully. A mean follow-up of 4.7 ± 2.15 years (between 1 and 9 years) revealed a functionally and cosmetically satisfactory total lower eyelid reconstruction in all patients.

Conclusions: This new technique seems to be a useful alternative for reconstruction of total and subtotal lower eyelid defects. The procedure seems to be superior since it requires considerably shorter operating time with no risk of flap failure. Moreover, this technique offers an excellent color and textural match for the reconstruction of total and subtotal lower eyelid defects extending the infraorbital area.

Key Words: total lower eyelid reconstruction, unequal Z-plasty, Mutaf triangular closure technique

(*Ann Plast Surg* 2017;78: 171–177)

Lower lid defects are often the results of surgical excision due to skin cancers, trauma, and burns, or they can be congenital.[1] Although several techniques have been described for reconstruction of small and medium lower lid defects, total lower lid defects require further surgery. Because the lower eyelid is an important functional and aesthetical unit, its reconstruction has always been a difficult task for reconstructive surgeons due to its peculiar anatomy and unique tissue composition. Here, we present a new technique for 1-stage reconstruction of complex total and subtotal defects of the lower lid reconstructions.

MATERIALS AND METHODS

Study Design and Patient Selection

All procedures performed in this study were in accordance with the ethical standards of the institutional research committee and with the 1964 Helsinki Declaration and its later amendments or comparable ethical norms. Patients gave informed consent before enrollment in the study. In over 12 years (between 2003 and 2015), this new technique was used in 24 patients, 13 men and 11 women, with total lower eyelid defects that resulted from excision of basal cell carcinoma (BCC) and trauma. The age range of the patients was between 45 and 72 years (Table 1).

The diagnosis of BCC was confirmed by preoperative biopsy in 22 patients. Nine of the patients had right lower eyelid involvement and 15 of the patients had left lower eyelid involvement. Two of the 4 patients had involvement of lateral canthal and lateral 1/3 of upper eyelid region involvement; the other 2 patients had medial canthal area and medial 1/4 of the upper eyelid involvement. A total of 22 patients had BCC; it was recurrent in 4 and primary in 18. Before the operation, an ointment with antibiotic was applied to the eye, and a protective lens was deployed. After excision of the tumor with an intact margin of 5 mm, the resultant defect is photographed; and for the layers of the defect to be repaired properly, surgical plan is done on the computer to determine the best flap design and orientation according to the individual requirements of each patient. Total excision of the tumor was confirmed by frozen section and reconstruction was performed. Planning to close the defect created in the form of a triangle can be done vertically or horizontally. This planning will be shaped according to the scar. A vertical scar that cuts through the eyelid margin should not be preferred because the contraction may cause ectropion. The direction of the resultant scars seems to be another critical factor in dealing with this flap. Repair of mucosa and tarsus should be made before closure of the skin according to the needs of patients.

For reconstruction of conjunctiva and tarsus, chondrocutaneous composite grafts were used in 16 patients and, in the other 8 patients, mucochondral composite grafts from nasal septum were used. Conchal cartilage fitting the size of the defect was obtained and was sutured to the defective region with the concave side facing the eye. In one patient whom the nasolacrimal duct was affected by the tumor, reconstruction of the lacrimal duct (Table 1) was done with a silicone tube (Jones tube) after tumor excision. Composite grafts are sutured under slight tension to the defect of the conjunctiva using inverted interrupted 6–0 vicryl sutures.

Seventeen of the 24 patients were anesthetized with local infiltration of 2% lidocaine with 1:200,000 epinephrines. Other patients, whose tumor affected the eyelids, medial canthus, or nasolacrimal ducts, required general anesthesia. We did not use a corneal protector.

Surgical Procedures

After tumor resection with a proper intact surgical margin, the resultant defect is surgically converted to an acute triangle (ABC) as the base of this triangle (AB) corresponding to the intercanthal line (Fig. 1). The flaps are outlined on the patient, using a ruler and a sterile skin marker. First, an imaginary point (a) is defined on the lateral margin (AC) of the triangle as the distance from the corner A to this point is equal to the base of the triangle. Then, 2 flaps are outlined in an unequal Z (45 degrees/60 degrees) manner. For this, beginning from point "a," the central limb of Z-plasty equal to the long margin (AC) is drawn with an angle of 60 degrees. Then, by drawing the upper limb of the Z-plasty with an angle of 45 degrees, 2 triangular flaps, flaps A and B, are obtained. Once the flaps are elevated, flap A is transposed over the defect area, and flap B is used for closure of the donor defect of flap A. According to various alternatives of defects, the mentioned flap modifications are shown in Figure 2 legend.

A chondral graft was placed to the posterior lamella of the lower eyelid to avoid scleral show and to reduce the lower eyelid laxity. The

Received November 12, 2015, and accepted for publication, after revision May 17, 2016.
From the *Division of Plastic Surgery, Bodrum Acıbadem Hospital, Muğla; and †Division of Plastic Surgery, Mustafa Kemal University, Hatay, Turkey.
This study was partially presented at the 28th Annual Congress of Turkish society of Plastic, Reconstructive and Aesthetic Surgeons, September 20–23, 2006, Ankara, Turkey.
Conflicts of interest and sources of funding: none declared.
Reprints: Metin Temel, MD, Department of Plastic and Reconstructive Surgery, School of Medicine, Mustafa Kemal University, Hatay, Turkey. E-mail: drmetintemel@hotmail.com, prsdrmetintemel@gmail.com.

ISSN: 0148-7043/17/7802–0171
DOI: 10.1097/SAP.0000000000000862

TABLE 1. Clinical Data

Demographic Data of Patients	n = 24/Median ± SD
Mean age, y	56.8 ± 8.3
Follow-up period, y	4.7 ± 2.15
Sex (male–female)	13M/11F
General/local anesthesia	7/17
Location of the lesions	
Medial total lower eyelid	n = 5
Lateral total lower eyelid	n = 6
Central lower eyelid	n = 13
Etiology	
Trauma	n = 2
BCC	n = 22
Primary	n = 18
Recurrent	n = 4
Reconstruction of conjunctiva and tarsus	
Chondrocutaneous composite grafts from ear	16
Mucochondral composite grafts from nasal septum	8

Median ± SD: Median ± standart deviation.

flaps were hanged by a 3/0 round needle monofilament nonabsorbable suture to the holes opened over the infraorbital rim to avoid ectropion and flap drooping due to gravity at the late period (Fig. 6B). The wound closure was done in layers, using 4/0 vicryl for subcutaneous tissue and 5–0 polypropylene for the skin. In all patients, the sutures were removed on the sixth postoperative day. No systemic antibiotic was used.

Illustrative Case Reports

Case 1

A 58-year-old man was referred to our institution with a BCC involving the entire left lower eyelid that was present for 10 years (Fig. 3). He is an outdoor worker. He has been in his job for 45 years. He has no family history. On local examination, he had an ulcerative lesion involving medial canthal region, 1 to 4 of upper eyelid medially, lacrimal caruncle, superior and inferior lacrimal papilla and puncta, and lacrimal canaliculi besides total of the lower eyelid. There were no palpable lymph nodes at the parotid region. The excision was done 5 mm far away from the surrounding of the lesion under general anesthesia. The lacrimal canaliculus and the lacrimal sac and nasolacrimal ducts were included in the specimen. The total defect was reconstructed with a horizontally planned V-Z flap. The conchal cartilage of the left ear was used for inferior tarsus reconstruction, and the saphenous vein was used for lacrimal canaliculi and conjunctiva reconstructions. Upper and lower eyelids were separated from each other 3 weeks after the first surgical operation.

Case 2

A 64-year-old man was admitted to our clinic for ectropion that resulted in a chronic ulcerative lesion on his right lower eyelid (Fig. 4). He had this lesion for 6 years. He has been working as a farmer for 50 years. He has no family history. On local examination, he had a scatricial ulcerative lesion on total of right lower eyelid and inferior lacrimal papilla and puncta. There was no palpable lymph node at the parotid region. A complete tumoral resection was performed 5 mm far away from the surrounding of the lesion, including the (1) complete lower lid, (2) lower ocular conjunctiva, (3) lower extraocular muscles, and (4) lacrimal lower canaliculus, under local anesthesia. The surgical

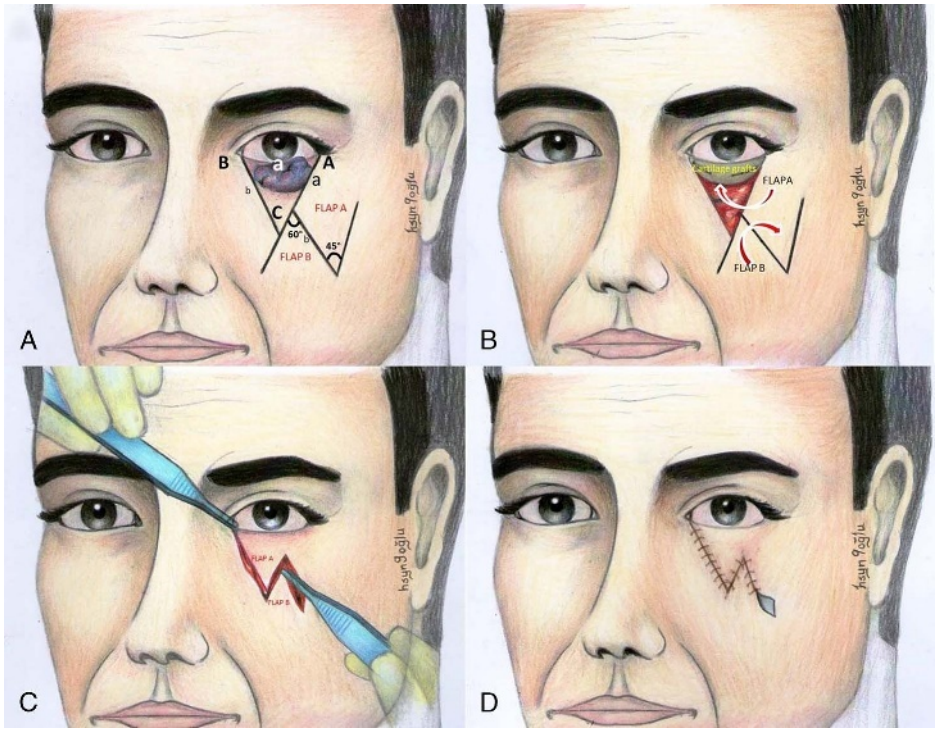

FIGURE 1. The design of Mutaf triangular closure technique adapted to the lower lid region. A, Flap design for vertically oriented to total lower lid defects. B, Once the flaps are elevated, "flap A" is transposed over the defect area and "flap B" is used for closure of the donor defect of "flap A." C, The skin flaps were fixated with nonabsorbable sutures upwardly to the infraorbital rim. D, The wound closure was done in layers.

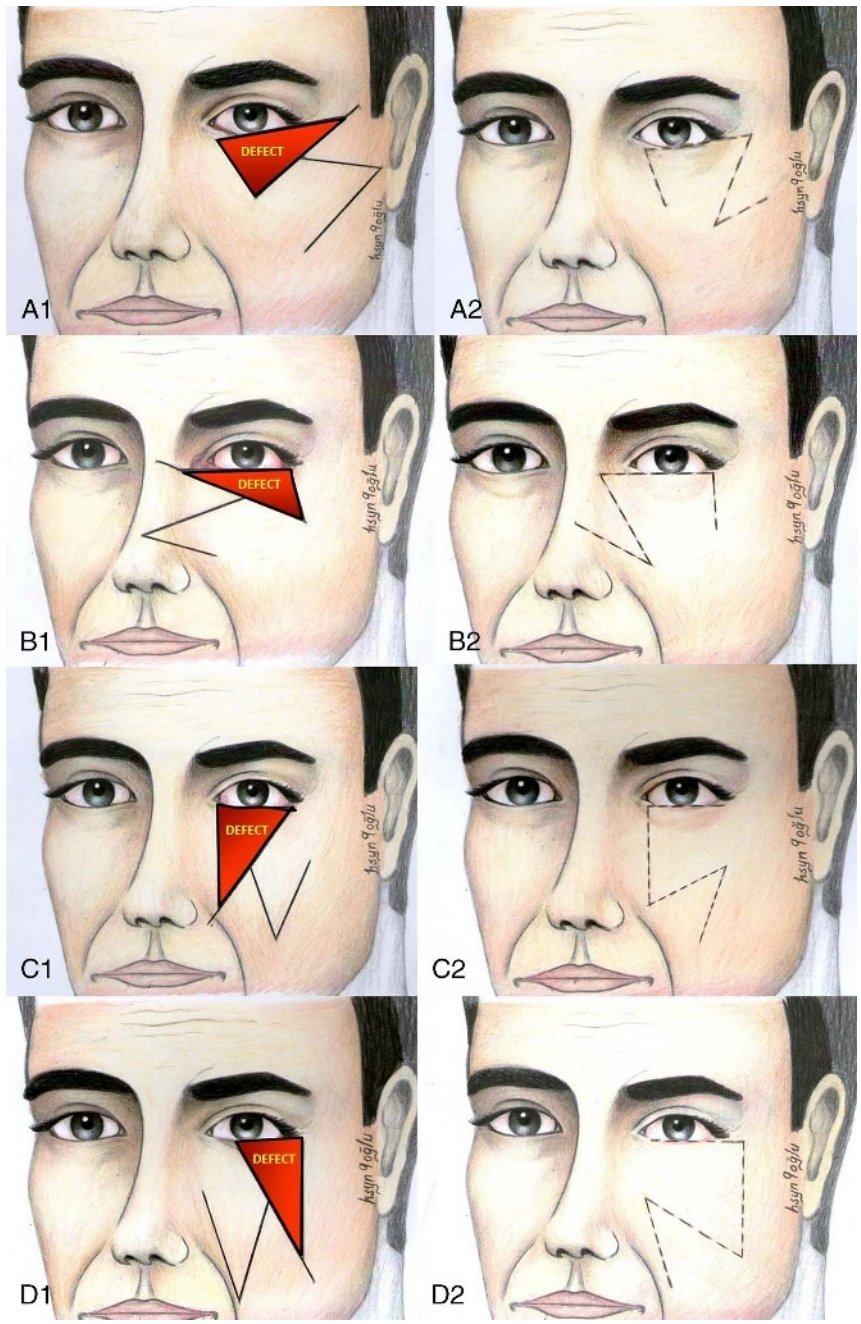

FIGURE 2. Various designs of Mutaf triangular closure technique for different defect positions and view of final scars. A1–2, The horizontal flap planning for the total laterally located lower lid defects and the view of proposed scarring. B1–2, The horizontal flap planning for the total medially located lower lid defects and the view of proposed scarring. C1–2, The vertical flap planning for the total medially located lower lid defects and the view of proposed scarring. D1–2, The vertical flap planning for the laterally located total lower lid defects and the view of proposed scarring.

reconstruction was planned as follows: (1) soft tissues by a V-Z flap, (2) tarsoconjunctival layer by conchal cartilage and skin composite graft from right ear, and (3) lacrimal drainage by a conjunctivorhinostomy with tube of Jones.

Case 3

A 56-year-old female patient was admitted to our clinic with an ulcerated lesion which involved 3/4 of the right lower eyelid, lateral canthal region, and 1/4 of the upper eyelid (Fig. 5). Incisional biopsy revealed that the lesion was BCC. The patient underwent surgical resection under general anesthesia. The involved tissue was resected with a 5-mm surgical border. For the reconstruction of the lower eyelid tissue defect, a chondrocutaneous composite graft was used for restoring posterior lamellar region and a vertically planned triangle flap was used for reconstructing the anterior lamellar layer. For the reconstruction of the upper eyelid defect, a 2-stage

FIGURE 3. A 58-year-old man was referred to our institution with a BCC involving the entire left lower eyelid that was present for 10 years. A, The BCC that involved the total lower eyelid and ¼ of the upper eyelid. B, Computer-assisted preoperative planning. C, The intraoperative markings of triangular defect closure technique. D, The reconstruction of the conjunctiva and the tarsus by chondral graft. E, The reconstruction of the lacrimal drainage system by the saphenous vein and one of its branches. F, The view of the opaque solution drainage from the conjunctiva to the lacrimal system. G, The fusion of the lower and upper eyelids after the first operation. H, The anterior view of the upper and lower eyelids after the separation of the eyelids. I, The lateral chin-up position view of the bilateral lower eyelids focused on the symmetry. The picture is taken in the late postoperative period (first postoperative year).

Fricke flap was planned. View of the first stage and late period view are shown.

Case 4

A 54-year-old female patient was admitted to our clinic with an ulcerated lesion which involved 4/4 of the right lower eyelid, the lateral canthal region, and 1/3 of the upper eyelid (Fig. 6). Incisional biopsy revealed that the lesion was BCC. The patient underwent surgical resection under general anesthesia. The involved tissue was resected with a 5-mm surgical border. For the reconstruction of the lower eyelid tissue defect, a chondrocutaneous composite graft was harvested from the right ear and used for restoring posterior lamellar region. The composite chondral graft was stabilized to the infraorbital rim by suturing with nonabsorbable sutures the holes that were created over infraorbital rim by a drill. A horizontally planned triangle flap was used for reconstructing the anterior lamellar layer and lower eyelid. For the reconstruction of the upper eyelid defect, a 1-stage Fricke flap was designed. The Fricke flap was transferred to the defect area by a tunnel and the part of the flap that was under the tunnel tissue was deepithelized.

Case 5

A 54-year-old male patient was admitted to our clinic with an ulcerated lesion which involved 4/4 of the lower eyelid (Fig. 7). Incisional biopsy revealed that the lesion was BCC. The patient underwent surgical resection under general anesthesia. The involved tissue was resected with a 5-mm surgical border. For the reconstruction of the lower eyelid tissue defect, a chondrocutaneous composite graft was harvested from the right ear. A vertically planned triangle flap was used for reconstructing the anterior lamellar layer.

RESULTS

The authors successfully carried out this procedure on 24 patients. Afterward, the lower eyelid was reconstructed by performing the proposed technique. There were 4 patients whose medial and lateral canthal regions and upper eyelids were influenced. Two of these 4 patients' medial canthal region and ¼ upper eyelids were influenced. The glabellar flap was applied for one of these 2 patients, and a 2-stage Mutaf unequal Z-plasty procedure was applied to another patient. The other 2 of these 4 patients' lateral canthal region and 1/3 upper eyelid were affected. Lateral canthal region and upper lateral eyelid were reconstructed by Fricke flap for another 2 patients. Six patients had lower eyelid tumors located medially and very close to the canaliculus. Thus, 4 of the 6 patients underwent conjunctivorhinostomy by Jones tube. For 2 of the 6 patients, the lacrimal drainage system reconstruction was performed by a saphenous vein graft. No patient had received radiotherapy before the operation.

Antibiotic-corticosteroid eye drops are recommended 3 times a day for 1 week. There was no patient with flap failure, hematoma, or

FIGURE 4. A 64-year-old male patient. A, The view of the preoperative anterior aspect. B, Computer-assisted preoperative planning. C, Surgical plan. D, Excisional defect. E, Immediate postoperative view. F, Late postoperative view after 1 year.

infection in the orbital area and none of our patients needed artificial tears beyond the postoperative period. There was no patient with ectropion and epiphora. A mean follow-up of 4.7 ± 2.15 years (2–8 years) revealed a functionally and aesthetically acceptable result in all patients. There was no tumor recurrence in any patient. The results were entirely satisfactory from a functional and aesthetic point of view.

DISCUSSION

The eyelids are complex structures, and their ideal reconstruction should repair as many of the missing elements as possible, replacing them with tissues of identical or similar structure. When a total lid reconstruction is planned, 3 main layers must be restored: (1) the external or skin, (2) the medial, and (3) the internal or conjunctival. The defects of the lower eyelid that are smaller than 1/3 of the whole lower lid's lengths are suitable for primary closure. However, the larger defects require further surgical procedures. Although many operative techniques were defined for the lower eyelid reconstruction, there is no ideal technique to be used for all defects yet.

In the previous literature, when a defect is larger than 1/3 of the whole lower lid's length,[2] it is advisable to use the advancement or transposition flaps from the cheek[3–6]; Hughes tarsoconjunctival flap,[5,6]

FIGURE 5. A 56-year-old female patient. A, Surgical plan. B, Excisional defect. C, View of the first phase. Incisions and flap elevation with supra-SMAS dissection. Transposition of flaps and view after suturing. D, The postoperative second-week oblique position views taken after the second stage. E, The postoperative first-year views taken at the closed situation of the eyelids. F, Late postoperative anterior view after 1 year.

FIGURE 6. A 54-year-old female patient. A, The view of the tumor that involved the whole lower eyelid and 1/3 of the upper eyelid and the horizontally planned triangular flap. B, A chondrocutaneous graft was taken from the right ear for the posterior lamellar reconstruction of the lower eyelid defect which was covered by triangular flap previously. For the posterior lamellar reconstruction, a Fricke flap and a triangular flap was transferred. The chondral graft was secured to the infraorbitally created holes by polypropylene sutures for stabilizing the tarsus. C, View after suturing. D, The postoperative second-month view.

the medial and lateral forehead regions flaps or nasolabial flaps, and nasolabial composite free flap should also be considered.[4,7–17] The most commonly used donor site for the reconstruction is the ipsilateral eyelid, and some well-established procedures have been described.[13,18,19] This excellent source of tissue is, of course, available for reconstruction only in limited supply and sometimes the need for other donor site areas.

The Mustarde cheek flap needs a full dissection, and it can be done in elderly patients, but it is not suitable for young patients. Ectropion in the late period due to gravity and wound contraction is another disadvantage of this flap.[20] Rotational tarsal flaps from the lid remnant avoid the problem but can be used only for small defects. Orbicularis oculi myocutaneous flap must be raised by careful dissection and the size of the flap sometimes is not enough for reconstruction of the ultimately lower lid.[21] Upper eyelid musculocutaneous flaps were used for the lower eyelid.[22] This flap wide is limited with the upper eyelid. So it could not be used for wide lower eyelid defect. Forehead flaps may be used for total lower eyelid reconstruction. However, they often require a 2-stage surgical procedure. Moreover, forehead skin is extremely thick and bulky for lower eyelid, donor site scar is quite visible, and in late period depending on gravity, ectropion develops.[23,24] The glabellar flap can reconstruct the wide defect on lower lid.[25] Donor site defect is covered with skin grafting, and also 2-stage operations are needed. The Hughes tarsoconjunctival flap is another alternative method for the reconstruction of lower eyelid defects. However, this method inevitably must raid the unaffected upper eyelid for donor tissue, which is a major disadvantage. Besides, when a full-thickness defect is substantial, it cannot be reconstructed with a tarsoconjunctival flap alone. Moreover, this technique is a 2-stage procedure in which the eye must remain closed until the second stage.[26] We believe that the technique of Scuderi and Rubino,[27,28] in which they reconstructed the posterior lamellar layer by chondromucosal island flap, is limited by some factors such as need of a skin graft for anterior lamella reconstruction, loop dissection, scarring of lateral aspect of the nasal skin, need of late period revisions, the nasal valve distortion resulted by scarring due to the incision of nasal cartilages, and late onset of ectropion of the eyelid because of the skin graft contracture, which is used for anterior lamellar reconstruction.

Even deltopectoral flap and free flaps (such as the dorsalis pedis, radial forearm flap, and free posterior auricular chondrocutaneous flap)[29–32] have been considered as an option, but only for simultaneous upper and lower reconstructions. Although such flaps are suitable alternatives for large defects of the periorbital region, they have a high morbidity due to removal of large tissue. Also, these flaps are very bulky, and thinning of the flap is often required. Eyelid retraction in the long-term is another disadvantage of such techniques. In partial defects, the color and tissue compatibility of these flaps are unfavorable.[33,34]

The Mutaf triangular closure procedure was first described by Mutaf et al[35] in 2007. They reported the use of Mutaf triangular closure procedure for the closure of large meningomyelocele defects. To our knowledge, this is the first clinical series on the use of this procedure for the reconstruction of total lower lid defects. We present this new technique for reconstruction of the entire lower lid defects by manufacturing a 3-layer composite skin-cartilage-mucosal unit that is 3-dimensionally and anatomically tailored. The V-Z flap is a random local flap technique. There is no need for skin graft to cover the donor site defect. Donor site could close primarily. The cheek tissue is used for closure of lower eyelid defect and so this flap can cover the wide defects. However, V-Z flap does not cover only lower lid. It may used near the total defects of both eyelids at the same side. However, as shown in case 1, loss of the total lower eyelid, medial canthus, and with 1/5 of the upper eyelid had a defect, all the skin defects were repaired with a single flap. Three weeks after the first operation it is divided into upper and lower eyelids cut off from each other. This method is a simpler, single-stage process; does not damage the upper lid; and, above all, is less invasive than the other techniques, and at the same time

FIGURE 7. A 54-year-old male patient with a tumor that totally invaded the lower eyelid. A, The intraoperative planning. B, Excisional defect and incisions and flap elevation with supra-SMAS dissection. C, View after suturing.

allows a good functional and aesthetic reconstruction. It presents the reconstructive surgeon with several advantages over other methods. Our technique has the advantage of being a 1-stage procedure. There have been other descriptions of pedicle or free prefabricated flaps for the reconstruction of total and subtotal defects of the lower eyelid in the literature. Unfortunately, they are complex and time-consuming procedures. Our procedure is simpler, does not require long-term eye occlusion, and is a time-saving alternative for eyelid reconstruction.

Advantages of this technique include the following: similar colors and textures were used, the flaps have a good and reliable blood supply and provide adequate and sufficient tissues, excellent aesthetic and functional reconstructions of the lower eyelid are provided, and 1-stage operations are more acceptable surgical procedures for patients. Flap donor area is closed primarily due to graft and the graft donor area scar formation of the complications was encountered in the field. Tarsus reconstruction uses cartilage to keep the eye open and prevents the development of ectropion.

The major disadvantage of this technique is that it is not convenient for the patients with the large unclosable defects by local flaps, who underwent surgical excisions, and patients who received radiotherapy or need exenteration. Also, residual scarring over the cheek region and a distortion of the cheek and nasolabial region may occur after flap transposition.

CONCLUSIONS

As a result of other flap procedures, the procedure seems to be superior since it requires considerably shorter operating time with no risk of flap failure. Moreover, this technique offers an excellent color and textural match for the reconstruction of total and subtotal lower eyelid defects extending the infraorbital area. In the same operation, the 4-layer reconstruction and lacrimal canal drainage could be done. With careful surgical planning, the final scars can be aligned with the relaxed skin tension and/or the contour lines.

Total lower lid reconstruction is a 1-stage procedure that can take place even under local anesthesia with sedation. The procedure ensures good functional and aesthetic results because it repairs all the missing tissue levels.

ACKNOWLEDGMENT

The authors thank Dr Hüseyin Dokuzoğlu for providing medical artwork.

Informed consent was received for publication of the figures in this article.

REFERENCES

1. Arita R, Mori N, Shirakawa R, et al. Meibum color and free fatty acid composition in patients with meibomian gland dysfunction. *Invest Ophthalmol Vis Sci*. 2015; 56:4403–4412.
2. Barraco P, Hamedani M, Ameline-Audelan V, et al. Surgical treatment of eyelid tumors. *J Fr Ophtalmol*. 2003;26:92–102.
3. McGregor IA, Morgan G. Axial and random pattern flaps. *Br J Plast Surg*. 1973; 26:202–213.
4. Tenzel RR, Stewart WB. Eyelid reconstruction by the semicircle flap technique. *Ophthalmology*. 1978;85:1164–1169.
5. Herde J, Krause A, Bau V. Results of the Hughes operation. *Ophthalmologe*. 2001;98:472–476.
6. Hughes WL. Total lower lid reconstruction: technical details. *Trans Am Ophthalmol Soc*. 1976;74:321–329.
7. Porfiris E, Georgiou P, Harkiolakis G, et al. Island mucochrondrocutaneous flap for reconstruction of total loss of the lower eyelid. *Plast Reconstr Surg*. 1997; 100:104–107.
8. Yildirim S, Gideroglu K, Akoz T. Application of helical composite sandwich graft for eyelid reconstruction. *Ophthal Plast Reconstr Surg*. 2002;18:295–300.
9. Mehrotra ON. Repairing defects of the lower eyelid with a free chondromucosal graft. *Plast Reconstr Surg*. 1977;59:689–693.
10. Furnas DW, Furnas H. Angular artery flap for total reconstruction of the lower eyelid. *Ann Plast Surg*. 1983;10:322–325.
11. Jackson IT, Dubin B, Harris J. Use of contoured and stabilized conchal cartilage grafts for lower eyelid support: a preliminary report. *Plast Reconstr Surg*. 1989; 83:636–640.
12. Marks MW, Argenta LC, Friedman RJ, et al. Conchal cartilage and composite grafts for correction of lower lid retraction. *Plast Reconstr Surg*. 1989; 83:629–635.
13. Mustarde JC. Major reconstruction of the eyelids: functional and aesthetic considerations. *Clin Plast Surg*. 1981;8:227–236.
14. Siegel RJ. Palatal grafts for eyelid reconstruction. *Plast Reconstr Surg*. 1985;76: 411–414.
15. Vasconez LO, Gamboa-Bobadilla M, Core GB. Treatment of paralytic ectropion with composite chondrocutaneous graft. *Ann Plast Surg*. 1994;33:557–560.
16. Zbylski JR, LaRossa DD, Rich JD. Correction of lower eyelid ptosis in the anophthalmic orbit with an autogenous ear cartilage graft. *Plast Reconstr Surg*. 1978;61:220–224.
17. van der Meulen JC. The use of mucosa-lined flaps in eyelid reconstruction: a new approach. *Plast Reconstr Surg*. 1982;70:139–146.
18. Holmstrom H, Bartholdson L, Johanson B. Surgical treatment of eyelid cancer with special reference to tarsoconjunctival flaps. A follow-up on 193 patients. *Scand J Plast Reconstr Surg*. 1975;9:107–115.
19. Atik B, Tan O, Bekerecioglu M, et al. Reconstruction of lower eyelid defects using a cross upper eyelid flap composited with ear cartilage. *Dermatol Surg*. 2007;33: 709–712.
20. Sugg KB, Cederna PS, Brown DL. The V-Y advancement flap is equivalent to the Mustarde flap for ectropion prevention in the reconstruction of moderate-size lid-cheek junction defects. *Plast Reconstr Surg*. 2013;131:28e–36e.
21. Han J, Kwon ST, Kim SW, et al. Medial and lateral canthal reconstruction with an orbicularis oculi myocutaneous island flap. *Arch Plast Surg*. 2015;42:40–45.
22. Maghsodnia G, Ebrahimi A, Arshadi A. Using bipedicled myocutaneous Tripier flap to correct ectropion after excision of lower eyelid basal cell carcinoma. *J Craniofac Surg*. 2011;22:606–608.
23. Lesavoy MA, Kohan E. Total upper and lower eyelid reconstruction using an expanded forehead flap. *Ann Plast Surg*. 2011;67:502–504.
24. Schechter EM, Kosutic D. Chimeric upper eyelid—supraorbital flap reconstruction. *Plast Reconstr Surg Glob Open*. 2015;3:e399.
25. Bajaj MS, Sethi A. Complicated eyelid reconstruction after an unusual glabellar flap repair. *Acta Ophthalmol Scand*. 2000;78:599–600.
26. Rohrich RJ, Zbar RI. The evolution of the Hughes tarsoconjunctival flap for the lower eyelid reconstruction. *Plast Reconstr Surg*. 1999;104:518–522; quiz 523; discussion 524–516.
27. Scuderi N, Rubino C. The use of an island chondromucosal flap in eyelid reconstruction: preliminary report. *Plast Reconstr Surg*. 1993;92:1409–1410.
28. Scuderi N, Rubino C. Island chondro-mucosal flap and skin graft: a new technique in eyelid reconstruction. *Br J Plast Surg*. 1994;47:57–59.
29. Gujjalanavar RS, Girish AC. Total upper and lower eyelid reconstruction using deltopectoral flap. *Indian J Plast Surg*. 2013;46:581–583.
30. Thai KN, Billmire DA, Yakuboff KP. Total eyelid reconstruction with free dorsalis pedis flap after deep facial burn. *Plast Reconstr Surg*. 1999;104:1048–1051.
31. Rampazzo A, Gharb BB, Chi Chen H. Total lower eyelid reconstruction with free posterior auricular chondrocutaneous flap. *J Plast Reconstr Aesthet Surg*. 2010; 63:e384–e386.
32. Ghadiali LK, Patel P, Levine JP, et al. Microvascular free flap for total eyelid reconstruction with a visually useful eye. *Ophthal Plast Reconstr Surg*. 2014 Oct 8. [Epub ahead of print].
33. Porfiris E, Christopoulos A, Sandris P, et al. Upper eyelid orbicularis oculi flap with tarsoconjunctival island for reconstruction of full-thickness lower lid defects. *Plast Reconstr Surg*. 1999;103:186–191.
34. Scuderi N, Rubino C, Bertozzi E. Clinical use of a new axial chondro-mucosal flap in wide full-thickness eyelid reconstructions. *Ophthalmic Surg Lasers*. 1999;30:91–97.
35. Mutaf M, Bekerecioglu M, Erkutlu I, et al. A new technique for closure of large meningomyelocele defects. *Ann Plast Surg*. 2007;59:538–543.