Consolidative Technique Otoplasty: Comprehensive Approach in Combining Techniques

Metin Temel

Aesthetic Plastic Surgery

ISSN 0364-216X

Aesth Plast Surg
DOI 10.1007/s00266-016-0699-5



Aesth Plast Surg
DOI 10.1007/s00266-016-0699-5

INNOVATIVE TECHNIQUES AESTHETIC

Consolidative Technique Otoplasty: Comprehensive Approach in Combining Techniques

Metin Temel[1]

Received: 11 May 2016 / Accepted: 24 August 2016

Abstract
Background This study aimed to present the long-term results of the consolidative technique otoplasty (CTO).
Methods Patient age, sex, duration of follow-up, and how the deformity (bilateral-unilateral) occurred were determined. The kind of anesthesia, duration of surgery, surgical techniques used during the operation were reported, and the preoperative and postoperative distances between the ear and head were measured at four points (SUP: The highest point of the helix; SCA: the concha superior sticking points; ICA: stick point of Concha at the inferior; and lobular). Early- and late-term complications were recorded in the postoperative period.
Results A total of 63 (21M–42FM) patients whose average age of 21:41 ± 8.96 (7–41), 119 ears (Right: 58/Left: 61) were operated on with this technique between 2013 and 2015. Mean follow-up was 18:22 ± 9:42 months. Anterior scoring was performed for three patients; concha resection was performed in 17 patients. Fifty-five patients were operated on as primary otoplasties and eight were secondary otoplasties. When the preoperative and postoperative SUP, SCA, ICA, and lobule measurements for both ears were compared, the postoperative values were found to be significantly decreased ($p < 0.001$).
Conclusions This technique may be an alternative in the repairs of prominent ears, and it provides an intervention opportunity for all the anatomical structures.

✉ Metin Temel
drmetintemel@hotmail.com

[1] Department of Plastic and Reconstructive Surgery, School of Medicine, Mustafa Kemal University, Antakya, Hatay, Turkey

Level of Evidence V This journal requires that authors assign a level of evidence to each article. For a full description of these Evidence-Based Medicine ratings, please refer to the Table of Contents or the online Instructions to Authors www.springer.com/00266.

Keywords Prominent ear · Otoplasty · Combination of surgical technique

Introduction

The prominent ear is the most common congenital anomaly of the outer ear [1–3]. The deformity may be in the form of conchal hypertrophy, less development of the antihelix, clarity of lobule, or combinations [4, 5]. More than 200 surgical techniques, including non-surgical correction, minimally invasive surgery, and cartilage excision, have been reported for the correction of prominent ears. These methods can be ranked as antihelix-forming techniques, conchal pit, and lobular-orientated techniques [6–10]. However, there is no consensus on a single method.

In prominent ear operations, while deciding on the operation technique, the deformity, patient age, and the elasticity of the ear cartilage in the patient should be considered [11, 12]. Additional ear abnormalities (skin tag, Darwin tubercle) should also be considered. Transverse growth and the conchal depth of ears is completed at 6 years of age regardless of gender, but vertical growth continues until 11–12 years [13]. Therefore, the operation in pediatric patients should be carried out so as not to cause damage to changes that develop at an older age [14]. Independent from the otoplasty technique, improved patient quality of life and self-esteem and high patient satisfaction are reported [4, 15]. While deciding on the

Published online: 09 September 2016

operation, attention should be paid to the following: whether appropriate ear development has been completed, the amount of psychological pressure created by the deformity in the patient, and the flexibility of the ear cartilage [1]. There is no consensus on the time of operation. However, public opinion is that the child should be operated on at around 5–6 years of age to begin to socialize [16, 17].

The surgical procedure is determined by the abnormalities in the ear by following the published algorithms [18]. We perform otoplasty operations utilizing algorithms in our clinic. We think that algorithms created by Janz and Janis provide good guidance, particularly for surgeons in the learning process for tolerance and to make the right decision for surgery [7, 19].

In this study, we aimed to present the long-term results of the comprehensive approach in combining techniques with a new surgical technique.

Materials and Methods

Consent was obtained from the local ethics committee for this study. Preoperative consent was received from all patients. A detailed otolaryngologic examination of the patients was made. Patients with connective tissue disease, bleeding disorder identified in preoperative investigations, congenital anomalies requiring operations outside the pinna and requiring psychiatric treatment were excluded from the study.

The age of the patient, sex, duration of follow-up, and how the deformity (bilateral–unilateral) occurred were determined. The kind of anesthesia surgery, duration of surgery, and surgical techniques used during the surgery were reported, and the distance between the head and the ear preoperatively and postoperatively were measured at four points (SUP: The highest point of the helix; SCA: the concha superior sticking points; ICA: stick point of Concha at the inferior; lobular) (Fig. 1) [20]. Complications in the first month are considered early complications, and complications between 1 month and 1 year are late complications [7, 21]. Early and late postoperative complications were recorded.

First-generation cephalosporin group of antibiotics was given in the perioperative period. The operation was performed with local or general anesthesia depending on the age of the patient. Operations were performed with the patient in the supine position so that the intraoperative symmetry covering of both ears was visible. Transparent 3/0–4/0 polypropylene sutures with round needles are preferred for antihelix shaping and coca-mastoid saturation. If the needle of the suture materials is round, a possible fracture in the cartilage is prevented. In addition, as it is transparent or white in color, its visibility in the skin is reduced. 4/0 polypropylene is more appropriate to use in pediatric patients and adults with flexible cartilage; 3/0 polypropylene for shaping is more suitable to use in patients with a hard cartilage structure as it is stronger and has less risk of breakage during the operation.

Surgical Technique

Both the ears of the patients were covered by sterile cloths after disinfecting with povidone iodine. By a sterile marking pen, a 1.5–2-cm-wide area was marked elliptically at the location of the new antihelix in the posterior aspect of the ear. A combination of 1 % lidocaine and 1/100,000 epinephrine was administered to the post-auricular and conchal bowl region by a 30-gage insulin injector as infiltration anesthesia. Then, at the post-auricular area, a 1.5–2-cm-wide skin area was deepithelized. The planned antihelix is centered on the deepithelized skin area. (Figure 2a). The perichondrium is elevated and removed from the inferior order of the deepithelized area, and the muscles are removed from their attachments. While performing conchal cartilage resection, the upper border of the concha is determined by a 30-gage insulin needle to prevent permanent deformities and distortion between the conchal cartilage and antihelix intersection zone (Fig. 2b). If the concal depth is more than 1.5 cm, the crescentic conchal cartilage resection is performed at the perichondrium removed area (Fig. 2c). The conchal resection is performed narrower than the determined resection borders. After cartilage resection, the resultant edges are sutured together using clear polypropylene suture. The cartilage resection should be done under 4 mm width to avoid excess skin at the conchal fossa. Then, for forming the antihelix, the proposed anti-helical fold is determined by means of a 30-gage insulin needle which is used as a guide and is passed through the anterior surface to the posterior surface of the ear. As for the cartilage laxity of the patient, two or three 4/0 or 3/0 round needle clear polypropylene Mustarde's sutures are placed in an 8 shape, and the antihelix is formed (Fig. 2d). While performing antihelix formation, if the cartilage is thick and stiff for shaping by sutures and the patient is older than 35 years, anterior scoring is helpful. For scoring, a 21-gage phlebotomy needle's sharp edge is used as a scalpel and two or three lines of longitudinal scoring are performed over the anterior surface of the corrected anti-helical zone. If this procedure is only at the anterior surface of the cartilage, a natural and smooth anti-helical fold can be achieved. If a greater gage needle is used, it may cause a full-thickness cartilage incision and may result in a sharp fold. A smaller gage needle causes inadequate correction. While scoring the cartilage, one should avoid full-thickness cartilage incision. Full-thickness cartilage incision results in a sharp anti-helical fold by

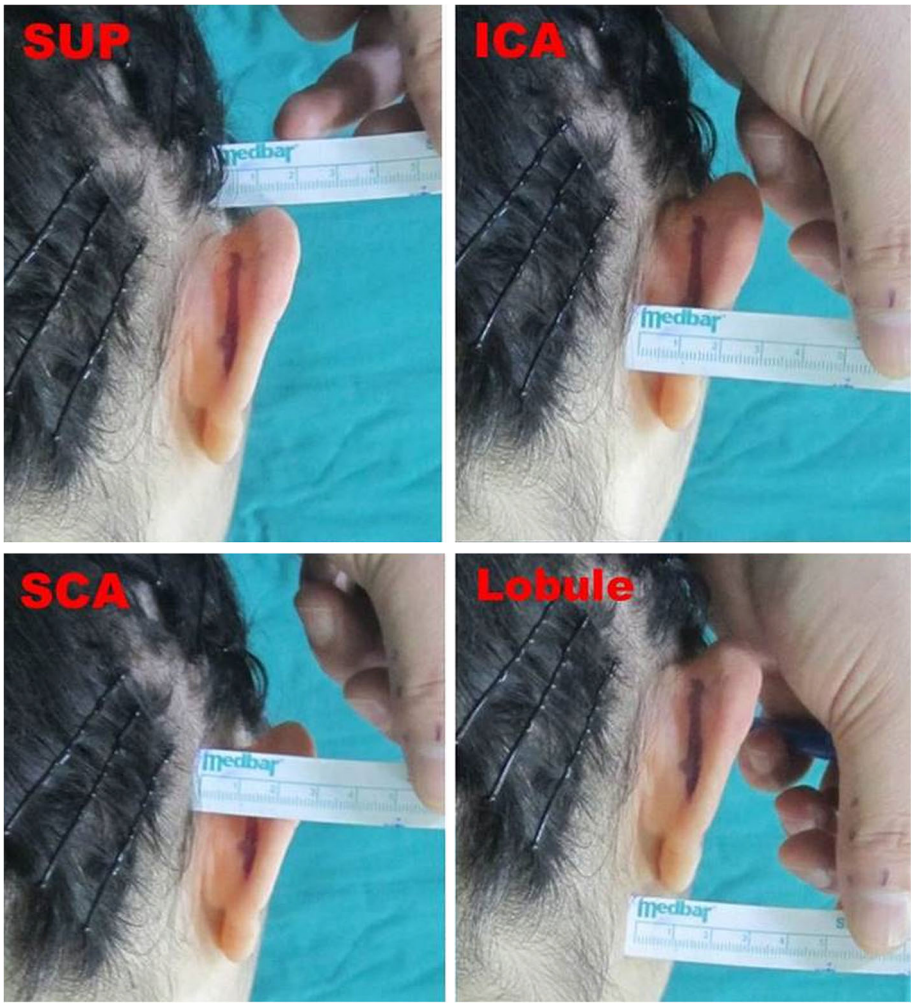

Fig. 1 Measurement points between the head and the ear

pulling forces while placing shaping sutures posteriorly. The deep abrasion could fracture the cartilage, causing sharp edges and angles. After placing antihelix-forming sutures, 0.5 cm dermal flaps are elevated from the medial and lateral borders of the deepithelized area (Fig. 2e). The superior leaf of (the lateral part of) the deepithelized skin island is used for covering the antihelix shaping sutures (Fig. 2f). The inferior part of (the medial part of) the deepithelized area is prepared as a dermal flap that is located medially to the ear and is used for covering the conchal cartilage resection area and also it is sutured to the muscle and mastoid fascia of the posterior ear using 4/0 round needle absorbable polyglycolic acid sutures (Vicryl®) similar to the description from Furnas [4] (Fig. 2g). The exposition of the sutures and posterior rotation of the ear is avoided by locating the flap over the permanent sutures. Additionally, the adhesion of the post-auricular dermis to the mastoid fascia avoids anatomic dead space and hematoma formation. An intraoperative minimal overcorrection prevents late-term recurrence of the deformity due to tissue laxity. The procedure is completed after placement of a couple of penrose drains, and subcutaneous and skin suturing to prevent postoperative hematoma formation (Fig. 2h).

The postoperative symmetry, the view of the antihelix and the light reflections are controlled by checking both the ears of the patient simultaneously at the end of the operation. Furthermore, a four-point measurement is done postoperatively. A bacitracin- and neomycin-containing ointment dressing is applied.

The patients who were operated on under the local anesthesia were discharged on the same day of the operation with a prescription for oral analgesics and prophylactic antibiotics. The dressings were changed at the first postoperative day. The patients who were operated on under general anesthesia were discharged at the first postoperative day after changing the dressings. The patients were warned not to wash the ear for 1 week. The sutures are removed between the 10th and 14th postoperative days. The patients were advised to use an elastic headband for 2 weeks postoperatively during the day and at night, and only at night for the following 2 weeks.

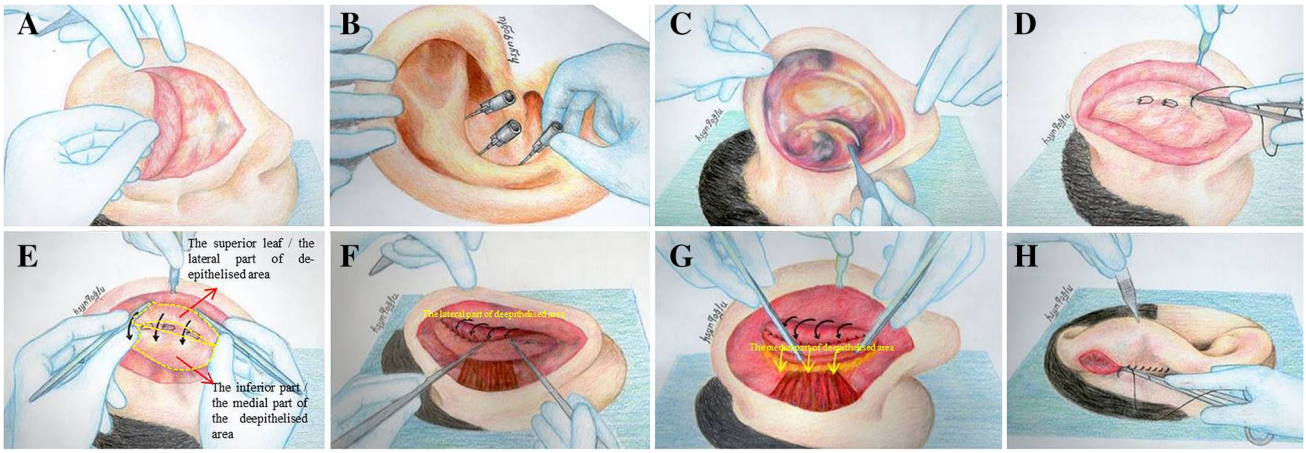

Fig. 2 Surgical technique. **a** The skin of the post-auricular area, a 1.5–2-cm-wide area, was deepithelized. The planned antihelix is centered on the deepithelized skin area. **b** Upper limit of conchal resection is determined by insulin injectors. **c** If the choncal depth is more than 1.5 cm, the crecentric choncal cartilage resection is performed at the area of perichondrium removal. The perichondrium is elevated and removed from the inferior order of the deepithelized area and the muscles are removed from their attachments. **d** As for the cartilage laxity of the patient, two or three 4/0 or 3/0 round needle clear polypropylene Mustarde sutures are placed in an 8 shape and the antihelix is formed. **e** After placing antihelix-forming sutures, 0.5 cm dermal flaps are elevated from the medial and lateral borders of the deepithelized area. **f** The superior/lateral leaf of the lateral part of the deepithelized skin island is used for covering the antihelix shaping sutures (Mustarde sutures). **g** The inferior/medial leaf of the deepithelized skin island is used for covering the conchal resection sutures and sutured to the posterior ear muscles. **h** The procedure is completed after placement of a couple of penrose drains after subcutaneous and skin suturing to protect against postoperative hematoma formation

Statistical Analysis

All statistical analyses were performed using GraphPad Prism V.5.0 (Graphpad Software Inc., CA, USA). The distribution between the preoperative and postoperative was assessed by the Kolmogorov–Smirnov test. The preoperative and postoperative SUP, SCA, ICA, lobule distance values were evaluated by the non-parametric Wilcoxon test (for paired samples). *P* values less than 0.05 were considered statistically significant at the 95 % confidence interval.

Results

Sixty-three (21M–42FM) patients with an average age of 21:41 ± 8.96 (7–41) years were operated on with this technique between 2013 and 2015. Patients included 29 children and 34 adults. The average follow-up time was 18:22 ± 9:42 months. The same operation was performed for 119 ears (right: 58/left: 61). Postoperatively, patients were asked about pain and their feelings about the correction of the defects. Concerning the anesthesia method used in the operations, general anesthesia was performed for five patients and local anesthesia was used for 58 patients. The average operation time was 67.26 ± 11.16 min. Anterior scoring was carried out on three patients; concha resection was performed in 17 patients. Fifty patients were primary otoplasties and eight patients were secondary otoplasties. Secondary otoplasty patients had been operated on with the incisionless suture technique and had recurrent deformities (Table 1).

When we evaluated complications, one patient who underwent scoring required drainage because of bleeding and hematoma and one patient developed dehiscence on the skin because of the use of a very tight headband. No patient experienced severe infectious complications such as surgical infection, perichondritis, or skin necrosis. In terms of late complications, the sutures opened in one patient, sutures could be seen under the skin in two patients in whom the technique was first applied, hypertrophic scars

Table 1 Patient data

Demographic data of patients	$N = 63$/Med ± SD
Age	21.41 ± 8.96
17-year old and younger	29
Above 17-year old	34
Follow-up period (months)	18.22 ± 9.42
Gender(male–female)	21M–42FM
The number of affected ear ($N = 119$)	R:58/L:61
Anesthesia (general anesthesia/local)	5/58
Operation time (min)	67.26 ± 11.16
Anterior scoring	3
Concha resection	17
Secondary otoplasty/primary otoplasty	8/55

R right, *L* left, *Median* ± *SD* median ± standard deviation

developed in one patient, the deformity reoccurred due to the opening of sutures in one patient, and an asymmetrical appearance due to a difference of more than 3 mm between the two ears occurred in two patients, one of them was operated on again by repeating Mustarde's sutures. The other patient was not operated on because he was pleased with the appearance of the ears. No inclusion cysts or outer ear way narrowing were observed in patients with this technique (Table 2).

When preoperative and postoperative SUP, SCA, ICA, and lobule values were compared, postoperative measurements were found to be significantly decreased ($p < 0.001$, Table 3).

Illustrative Case Reports

Case 1

A 15-year-old female patient with previous non-incisional otoplasty was seen in our clinic. She underwent otoplasty with local anesthesia. The preoperative examination showed significantly protruding ears with an ear–head distance of 25/24; 27/28; 26/26; 19/20 mm in the region of the SUP; SCA; ICA; lobule; at right/left ears, respectively. Also, marked anti-helical hypoplasia and cavum hyperplasia were present (Fig. 3a–d). Examination of the patient revealed exposure of the cartilage shaping sutures in both the anterior and posterior aspects of the ear. The auricular cartilage was soft and elastic. Based on the findings, the patient was operated on with this technique.

The postoperative first year after the intervention showed symmetrical SUP; SCA; ICA; and lobule distances of 12/13; 16/17; 17/15; and 18/18 mm, at the right/left ears, respectively. A newly formed anti-helical fold, smaller cavum concha, as well as a lobule set back in the auricular plane were evident (Fig. 3e–h). By this technique, there is no narrowing of the post-auricular fold unlike as expected results (Fig. 3g).

Table 2 Complication rates of consolidative technique otoplasty (values in %)

	$N = 63/\%$
Early-term complication	
Bleeding and hematoma	1/1.58
Infection	0
Dehiscence	1/1.58
Skin necrosis	0
Late-term complication	
Breaking of the stitches	1/1.58
Exposure of suture	2/3.17
Hypertrophic scar	1/1.58
Inclusion cyst	0
Residual deformity	1/1.58
Asymmetry	2/3.17
Patients required reoperation	1/1.58

Case 2

A 9-year-old otherwise healthy girl presented with bilateral prominent ears. Because of her markedly prominent ears, the child had often been teased. Physical examination revealed bilateral prominent ears, lack of helical fold definition, bilateral conchal hypertrophy, and prominent lobules. She had a choncal depth over 1.5 cm (Fig. 4a–d).

She underwent choncal resection combined with this technique. At 1.5 years after surgery, the patient demonstrated significant improvement in her anti-helical fold definition. She had more appropriately proportioned ears without conchal bowl excess and less prominent lobules. The patient was very satisfied with her outcome. The postoperative views are shown in Fig. 4e–h.

Case 3

A 38-year-old female patient suffered from bilateral prominent ears. She underwent conchal resection combined with the same surgical technique. The preoperative views are shown in Fig. 5a–d. The postoperative 20th-day views are shown in Fig. 5e–h.

Case 4

A 44-year-old female patient presented with a bilateral prominent ear deformity. Her two daughters also had the same deformity. The mother and the two young girls were treated by the same surgical technique. The preoperative (Fig. 6a–d) and the postoperative third-month views (Fig. 6e–h) are shown.

Discussion

The first data on prominent ear repair were published by Dieffenbach in 1845. Dieffenbach fixed the ear with post-auricular skin excision and concha mastoid ear suture to repair prominent ear in a patient [22]. Gibson and Davis demonstrated that the incision on one side of the cartilage contributes to the bend on the other hand [23] and then with this information, Converse reported anterior scoring and antihelix-forming techniques and its modifications [24–27]. Mustarde published an anti-helicalfold-forming technique made with only sutures using non-absorbable sutures in 1967 and 1963 [28, 29]. Furnas and Spira used a concha mastoid suture technique with antihelix plasty to reduce the

Table 3 The comparison of the changes in terms of preoperative and postoperative measurement values of ear to head distance in patients with consolidative technique otoplasty

	Preoperative right ear Median, IQR	Postoperative 1 year later right ear Median, IQR	*p* value *	Preoperative left ear Median, IQR	Postoperative 1 year later right ear Median, IQR	*p* value*
SUP (mm)	25 (24–26)	12 (12–13)	<0.001	25 (24–25)	13 (12–14)	<0.001
SCA (mm)	27 (26–28)	15 (15–16)	<0.001	27 (27–28)	16 (15–17)	<0.001
ICA (mm)	26 (25–26)	17 (16–18)	<0.001	26 (25–27)	16 (15–16)	<0.001
Lobule (mm)	23 (19–25)	19 (18–19)	<0.001	24 (20–24)	18 (18–19)	<0.001

IQR interquartile range (25–75 %), *SUP* most superior helical point, *SCA* superior conchal attachment, *ICA* inferior conchal attachment

* Wilcoxon Signed Ranks Test

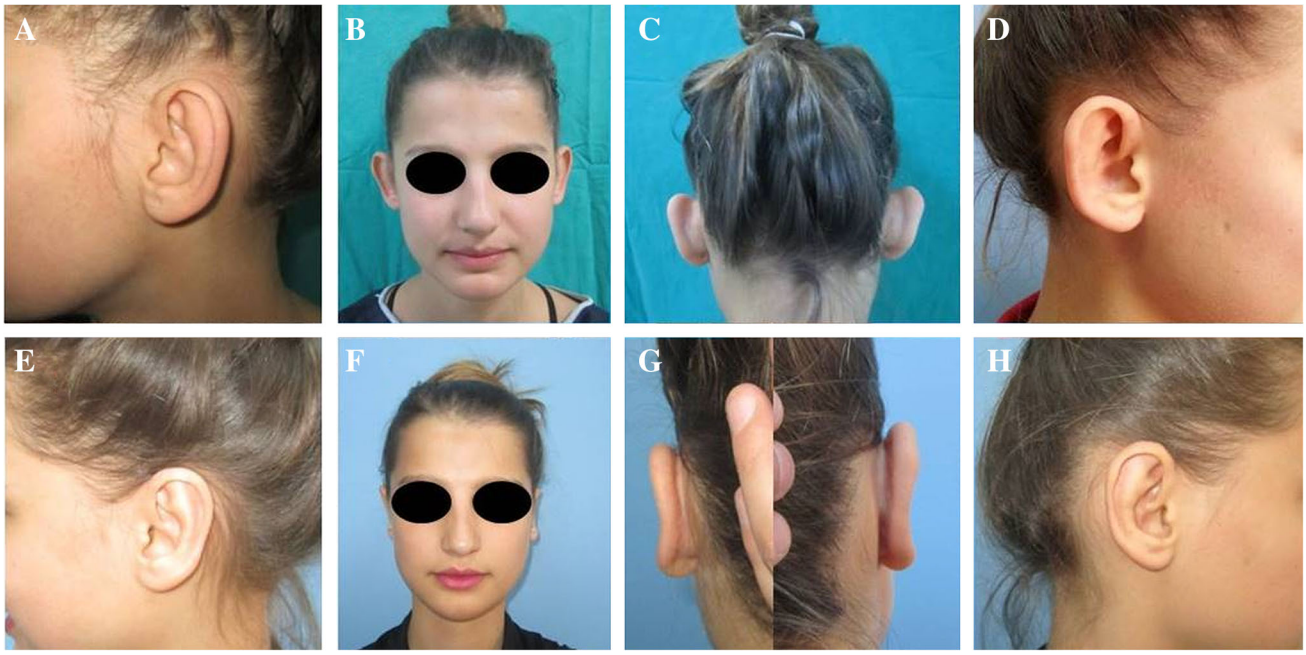

Fig. 3 A 15-year-old female patient with prominent ears. **a–d** The preoperative views. **e–h** The postoperative first-year views of the patient are seen. **g** By this technique, there is no narrowing of the post-auricular fold

distance between the helix and mastoid [4, 30]. Several techniques such as wedge resection and "fish tail-like" retro-lobular excision related with protruding lobule were published [30]. Taking the lobule to the back from the posterior direction with the mattress sutures is a useful technique published by Siegert [31]. Despite this development, there is no consensus on one method. After the specific deformity is determined, otoplasty should be planned according to the individual deformity and disfigurement needs of the ear [32].

When deciding on the ideal technique, if the patient is younger than 10-year old and has an elastic cartilage structure, forming techniques can be selected. However, incision, scoring, and excisional techniques should be combined if the patient is old and has a hard (stiff) cartilage structure [18, 33]. The methods previously accepted such as Mustarde antihelix plasty, resection of the concha, concha mastoid suture, anterior scoring, and backward rotation of the ear with dermal flaps from the posterior may be added to these techniques.

We use both the medial and lateral leaves of the dermal flap during deformity correction in the Consolidative Technique Otoplasty. The lateral and medial leaves of the dermal flap decrease the late-term complication risk of sutures by forming a durable coverage. We are using the lateral sheet to cover the Mustarde sutures. However, we use the medial leaf to cover the excision sutures of the conchal cartilage and hang on to the muscles in the posterior ear and mastoid fascia. The recurrence of the deformity through these maneuvers is blocked not only by

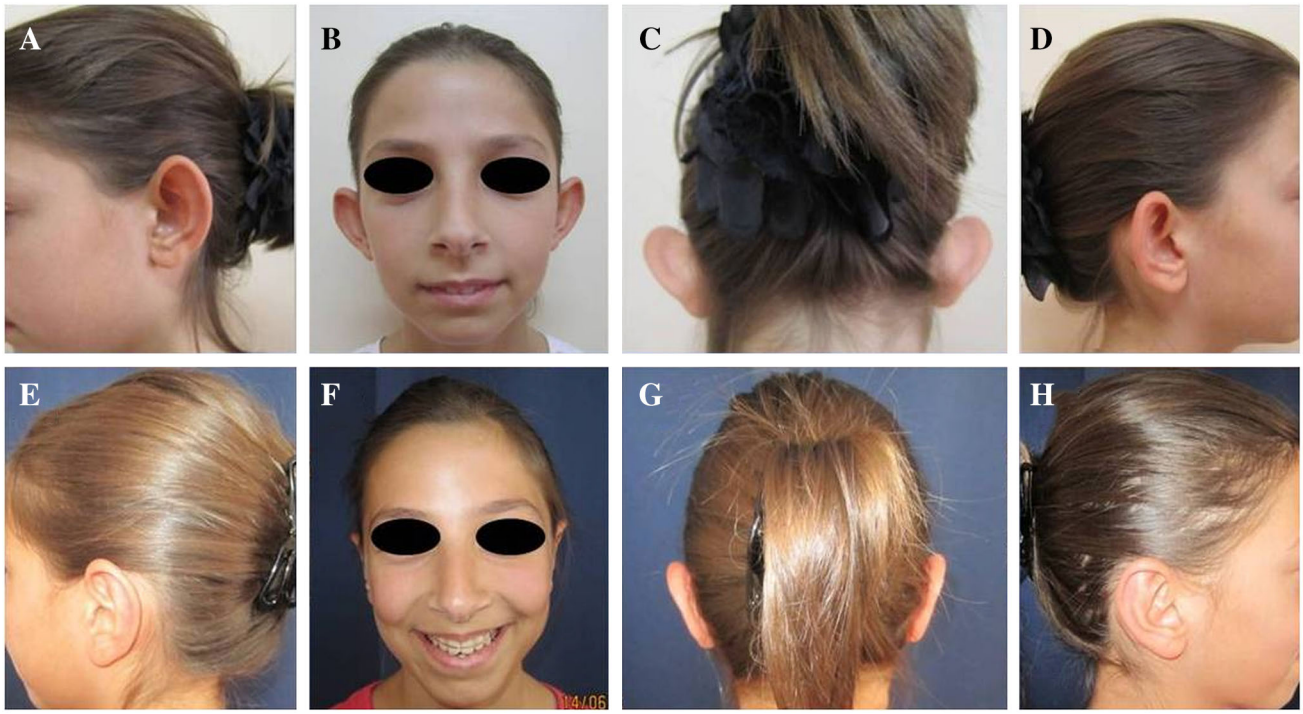

Fig. 4 A 9-year-old otherwise healthy girl presented with bilateral prominent ears. **a–d** The preoperative views are seen. **e–h** The postoperative views are seen

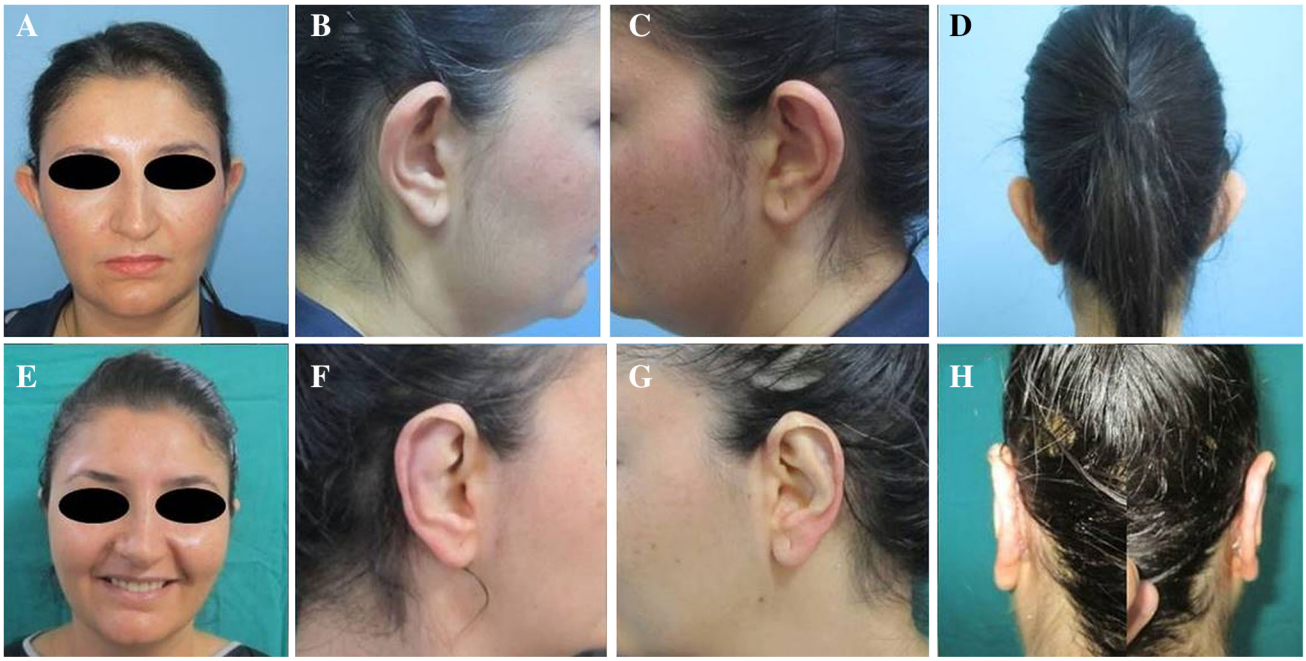

Fig. 5 A 38-year-old female patient suffered with bilateral prominent ears. **a–d** The preoperative views are seen. **e–h** The postoperative 20th-day views are seen

knot security of sutures but also through fibrotic adhesions caused by the dermal flap. Also, the development of dead spaces behind the ear is prevented through the suturing of the medial-based flap to the muscle and fascia in the mastoid region. Furthermore, the post-auricular sulcus is not narrowed with our technique. In our technique, we have used both the lateral and medial leaf of the deepitelized area. To our knowledge, this technique has not been used

Fig. 6 A 44-year-old female patient presented with bilateral prominent ear deformity. **a–d** The preoperative views. **e–h** The postoperative third-month views

before. We have observed less late-term complications compared with the other techniques reported in the literature (Table 2).

In the review of the literature, we recognize that Shokrollah et al. application is similar to our technique. However, Shokrollahi et al. [34] reported the early results of prominent ear repair technique with the lateral-based flap in 15 patients. They did not report exactly in which part of the ear the abnormalities occurred, and there is no information about the long-term results. When this lateral-based flap technique is used in combination with cartilage excision and suturing techniques, it can reduce the risk of exposition but this method does not seem very appropriate for patients with isolated conchal hypertrophy. Its combination with other techniques is needed. Basat et al. [35] have combined lateral-based flaps with Furnas and Mustarde techniques in 17 patients. However, the lateral-based flap will not provide the solution for patients with excessive conchal hypertrophy. Horlock et al. [36] and Sinha and Richard [37] have combined medial-based post-auricular flaps with Mustarde and Furnas techniques. They have reported that suture exposition did not occur, and the risk of the recurrence of deformity was 8 %. There is the danger of the potential space forming between the mastoid and the flap in the medial-based flap planning. However, this risk is less in the lateral-based flap. In our study, prominent ear deformity recurred in only one patient (1.58 %).

In the literature, different measurement techniques are available to evaluate the results of otoplasty. Crysdale and Messner made their measurements according to a Frankfort horizontal line, between the infra-orbital rim and the upper portion of the external ear canal. The desired difference between the two ears is not more than 2 mm [38]. We evaluated the results of the patients who underwent prominent ear operation by measuring the four regions of the ear. We present the results of our preoperative and postoperative patients who have completed one year in this study to measure the persistence of the technique. A significant difference between preoperative SUP, SCA, ICA, and lobule measurements and first-year postoperative measurements was recorded (Table 3; $p < 0.001$). Two patients had a difference of more than 2 mm between the two ears only detectable by a physician. Reoperation was required for asymmetry in one of these patients.

In cartilage excision techniques, complications such as post-auricular incision, soft tissue resections, and depending on this process, hematoma, scarring, and postoperative dressing requirements are common [39]. We applied this technique to 119 ears with concha resection in 17 of patients and anterior scoring in three patients. Suturing of the dermal flap to the mastoid fascia was performed in all

patients. We classify the complications encountered in patients who were operated on in this study, including early and late (Table 2) [7, 21]. We encountered bleeding in one patient, suture exposition in two patients who were operated on in the early period in the 18.22 ± 9.42 month follow-up. Also, we recorded suture opening in one patient and hypertrophic scars in one patient. Reoperation was needed only in one patient; we think this is an acceptable rate when compared to the literature [1, 40]. This operation was performed only with monofilament polypropylene suture, when multifilament mersilen is used, success rates may be further enhanced. In a study, Tan et al. compared Mustarde's suture technique and the Stenstrom anterior scoring technique, although patient satisfaction in both techniques was similar, it was reported that more than two operations were needed, and sinus formation and infection rates were more than normal due to the sutures in the patients who were operated on with the Mustarde technique [41]. Mustarde published the results of patients in two studies. In the first study, 264 ears were followed for 10 years and unsatisfactory results such as antihelix kink formation, opening sutures, sinus formation, the recurrence of prominent ear, and increase in the horizontal projection of the anti-tragus and lobule were observed [29]. He reported necessary measures to prevent the development of these complications. Then, he reported never encountering suture opening in 600 ears; the rate of sinus formation was 0.01 %, and reoperation is necessitated in 0.02 % of patients in 20 years [42]. The main reasons for differences in the rate of complications may be errors in the planning of the operation and choosing of suture material used in operations despite the same technique used in the process. Spira and Hardy have published their experiences with the Mustarde technique, but their success rate was not comparable, minor complications were common and deformity recurrence was often [43]. Reoperation was required more often with the use of monofilament suture.

Calder and Naasan Stenstrom stated that they had encountered 16.6 % complications and 8 % deformity recurrence during the 12-month follow-up period in 562 patients. These authors reported that 73.4 % of these complications were caused by failures in operation planning and 26.6 % resulted from a failure to apply the technique correctly [44]. Adamson et al. reported that revision necessity and the remaining traces were more than the cartilage-sparing techniques in 119 patients in whom conchal setback and anti-helical fold were formed [3]. Also, they reported that the upper pole of the ear was lateralized 40 % more compared to the middle and lower pole and indicated the necessity of revision at the rate of 6.5 %. We have seen the deformity repeat at a rate of 1.58 % with this technique. In our technique, we use monofilament sutures too; however, fewer revisional surgeries are required due to the use of dermal flaps in addition to cartilage shaping sutures. We think that the medial and lateral dermal flaps cause cohesiveness resulting in less suture dehiscence and recurrence of the deformity.

Conclusions

The surgical techniques should be determined by considering patient age, the structure of the ear cartilage, and the region of the prominent ear problems; maximum effort must be spent to get permanent results. Prominent ear deformity may arise from the concha, antihelix, or lobule. This technique may be an alternative in the repairs of prominent ears because it provides an intervention opportunity for all the anatomical structures.

Acknowledgments All procedures performed in studies involving human participants were in accordance with the ethical standards of the institutional research committee and with the 1964 Helsinki declaration and its later amendments or comparable ethical standards.

Compliance with Ethical Standards

Conflict of Interest The authors declare that they have no conflict of interest. None of the authors have a financial interest in any of the products, devices, or drugs mentioned in this article.

References

1. Kelley P, Hollier L, Stal S (2003) Otoplasty: evaluation, technique, and review. J Craniofac Surg 14(5):643–653
2. Paredes AA, Williams JK, Elsahy NI (2002) The constricted ear. Clin Plast Surg 29(2):289–299 **(viii)**
3. Adamson PA, McGraw BL, Tropper GJ (1991) Otoplasty: critical review of clinical results. Laryngoscope 101(8):883–888
4. Furnas DW (1968) Correction of prominent ears by conchamastoid sutures. Plast Reconstr Surg 42(3):189–193
5. Elliott RA Jr (1978) Complications in the treatment of prominent ears. Clin Plast Surg 5(3):479–490
6. Campbell AC (2005) Otoplasty. Facial Plast Surg 21(4):310–316
7. Janis JE, Rohrich RJ, Gutowski KA (2005) Otoplasty. Plast Reconstr Surg 115(4):60e–72e
8. Jeffery SL (1999) Complications following correction of prominent ears: an audit review of 122 cases. Br J Plast Surg 52(7):588–590
9. Rogers BO (1969) The classic reprint. A new operation for prominent ears based on the anatomy of the deformity by William H. Luckett, M.D. (reprinted from Surg Gynec Obst, 10: 635–637, 1910). Plast Reconstr Surg 43(1):83–86
10. Salgarelli AC et al (2009) Combined technique for the correction of prominent ears: results in 140 patients. Br J Oral Maxillofac Surg 47(7):545–549
11. Payasli C et al (2006) Traumatic prominent ear secondary to cartilage fracture without skin laceration or hematoma. Plast Reconstr Surg 117(3):1052–1053
12. Meagher PJ, Morrison WA (2001) An unusual presentation of bilateral prominent ears. Br J Plast Surg 54(4):366–367

13. Kalcioglu MT et al (2003) Anthropometric growth study of normal human auricle. Int J Pediatr Otorhinolaryngol 67(11): 1169–1177
14. Balogh B, Millesi H (1992) Are growth alterations a consequence of surgery for prominent ears? Plast Reconstr Surg 90(2): 192–199
15. Fritsch MH (2004) Incisionless otoplasty. Facial Plast Surg 20(4):267–270
16. Ganzer U (1998) Guidelines/algorithms of the German Society of Otorhinolaryngology, Head and Neck Surgery. Plastic reconstructive and esthetic operations in otorhinolaryngology, head and neck surgery. Laryngorhinootologie 77(10):599–601
17. Gosain AK, Kumar A, Huang G (2004) Prominent ears in children younger than 4 years of age: what is the appropriate timing for otoplasty? Plast Reconstr Surg 114(5):1042–1054
18. Naumann A (2007) Otoplasty—techniques, characteristics and risks. GMS Curr Top Otorhinolaryngol Head Neck Surg 6:Doc04
19. Janz BA et al (2009) Treatment of prominent and constricted ear anomalies. Plast Reconstr Surg 124(1 Suppl):27e–37e
20. Adamson PA, Litner JA (2007) Otoplasty technique. Otolaryngol Clin North Am 40(2):305–318
21. Heppt W, Trautmann Y (1999) Otoplastic techniques for the correction of protruding ears. HNO 47(8):688–694
22. Dieffenbach JF (1845) Die operative Chirurgie, section 3. F. A. Brockhaus, Leipzig, pp 258–267
23. Gibson T, Davis WB (1958) The distortion of autogenous cartilage grafts: its cause and prevention. Br J Plast Surg 10:257
24. Converse JM et al (1955) A technique for surgical correction of lop ears. Plast Reconstr Surg (1946) 15(5):411–418
25. Converse JM, Wood-Smith D (1963) Technical details in the surgical correction of the lop ear deformity. Plast Reconstr Surg 31:118–128
26. Chongchet V (1963) A method of antihelix reconstruction. Br J Plast Surg 16:268–272
27. Stenstroem SJ (1963) A "Natural" technique for correction of congenitally prominent ears. Plast Reconstr Surg 32:509–518
28. Mustarde JC (1963) The correction of prominent ears using simple mattress sutures. Br J Plast Surg 16:170–178
29. Mustarde JC (1967) The treatment of prominent ears by buried mattress sutures: a ten-year survey. Plast Reconstr Surg 39(4):382–386
30. Spira M et al (1969) Correction of the principal deformities causing protruding ears. Plast Reconstr Surg 44(2):150–154
31. Siegert R (2004) Correction of the lobule. Facial Plast Surg 20(4):293–298
32. Weerda H (2010) History of auricular reconstruction. Adv Otorhinolaryngol 68:1–24
33. Gosain AK, Recinos RF (2002) Otoplasty in children less than four years of age: surgical technique. J Craniofac Surg 13(4):505–509
34. Shokrollahi K, Cooper MA, Hiew LY (2009) A new strategy for otoplasty. J Plast Reconstr Aesthet Surg 62(6):774–781
35. Basat SO et al (2014) New otoplasty approach: a laterally based postauricular dermal flap as an addition to Mustarde and Furnas to prevent suture extrusion and recurrence. Aesthetic Plast Surg 38(1):83–89
36. Horlock N, Misra A, Gault DT (2001) The postauricular fascial flap as an adjunct to Mustarde and Furnas type otoplasty. Plast Reconstr Surg 108(6):1487–1490 **(discussion 1491)**
37. Sinha M, Richard B (2012) Postauricular fascial flap and suture otoplasty: a prospective outcome study of 227 patients. J Plast Reconstr Aesthet Surg 65(3):367–371
38. Messner AH, Crysdale WS (1996) Otoplasty. Clinical protocol and long-term results. Arch Otolaryngol Head Neck Surg 122(7):773–777
39. Fritsch MH (1995) Incisionless otoplasty. Laryngoscope 105((5 Pt 3 Suppl 70)):1–11
40. Strychowsky JE et al (2013) Incisionless otoplasty: a retrospective review and outcomes analysis. Int J Pediatr Otorhinolaryngol 77(7):1123–1127
41. Tan KH (1986) Long-term survey of prominent ear surgery: a comparison of two methods. Br J Plast Surg 39(2):270–273
42. Mustardé JC (1980) Results of otoplasty by the author's method. In: Goldwyn RM (ed) Long-term results in plastic and reconstructive surgery. Little, Brown, Boston, pp 139–144
43. Spira M, Hardy SB (1963) Management of the injured ear. Am J Surg 106:678–684
44. Calder JC, Naasan A (1994) Morbidity of otoplasty: a review of 562 consecutive cases. Br J Plast Surg 47(3):170–174