Body Contouring

Improvements in Vertebral-Column Angles and Psychological Metrics After Abdominoplasty With Rectus Plication

Aesthetic Surgery Journal
2016, Vol 36(5) 577–587

DOI: 10.1093/asj/sjv257
www.aestheticsurgeryjournal.com
OXFORD UNIVERSITY PRESS

Metin Temel, MD; Arif Türkmen, MD, FRCS, FRCS (Plast); and Ömer Berberoğlu, MD

Abstract

Background: Substantial fluctuations in body weight can result in diastasis recti and weakening of the connections between the lateral abdominal muscles and the rectus sheath.

Objectives: The authors sought to determine the postural and psychological effects of abdominoplasty with vertical rectus plication.

Methods: Forty women with substantial back and lumbar pain owing to abdominal lipodystrophy were evaluated in a prospective study. Preoperatively and 6 months postoperatively, patients underwent bidirectional radiography of the thoracic and lumbar regions. A visual analog scale (VAS), the Beck Depression Inventory (BDI), and the Nottingham Health Profile (NHP) were applied to assess physical, psychological, and quality-of-life changes following surgery.

Results: Significant improvements in posture, assessed in terms of lumbar lordosis, thoracic kyphosis, and the lumbosacral angle, were observed 6 months after abdominoplasty with rectus plication. Results of the VAS and BDI indicated significant improvements in pain and quality of life, respectively. Results of the NHP indicated significant postoperative improvements in fatigue, pain, and sleep.

Conclusions: Abdominoplasty with rectus plication improves posture by tightening the thoracolumbar fascia. In selected patients, abdominoplasty can reduce back and lumbar pain, thereby improving quality of life.

Level of Evidence: 4

Accepted for publication December 1, 2015; online publish-ahead-of-print January 12, 2016.

Individuals with abdominal lipodystrophy typically experience respiratory disorders as well as back and lumbar pain from alterations in body posture concomitant with this condition.[1,2] These individuals may encounter difficulties finding appropriately sized clothing, participating in sports, and performing daily activities. In addition, body-image and sexual disorders may develop in patients with abdominal lipodystrophy.[3] Almost all affected individuals attempt to lose weight by means of various methods, including medication, physical therapy, and supportive corsets.[2] For some patients, these methods fail to provide efficient, long-term improvement. These patients may choose to undergo surgery to ameliorate their health concerns, and in turn, their self-image and social life.

Dr Temel is a Clinical Assistant Professor, Division of Plastic Surgery, Mustafa Kemal University, Hatay, Turkey. Dr Türkmen is a Clinical Associate Professor, Division of Plastic Surgery, İstanbul University, İstanbul, Turkey. Dr Berberoğlu is a Plastic Surgeon in private practice in Gaziantep, Turkey.

Corresponding Author:
Dr Metin Temel, Division of Plastic Surgery, School of Medicine, Mustafa Kemal University, Hatay, Turkey.
E-mail: drmetintemel@hotmail.com

Presented at: the XXXIIth Annual Congress of the Turkish Society of Plastic, Reconstructive and Aesthetic Surgery in Trabzon, Turkey in September 2011.

Abdominoplasty has been found to relieve lumbar pain in selected patients with abdominal lipodystrophy.[4,5] The aims of this study were to determine the effects of abdominoplasty with rectus plication on the lumbosacral angle and on the extents of thoracic kyphosis and lumbar lordosis. In addition, we sought to objectively evaluate the social and psychological effects of abdominoplasty in patients with abdominal lipodystrophy. We assessed the deformities of abdominal skin and subcutaneous tissue[6] as well as the properties of myoaponeurotic structue of the abdominal wall using Nahas classifications.[7] To our knowledge, this study is the first to address the effects of abdominoplasty on vertebral-column angles and on concomitant quality-of-life metrics.

METHODS

Study Design and Patient Selection

This prospective study was approved by the Ethics Committee of the School of Medicine of Gaziantep University (Gaziantep, Turkey). All procedures were performed in accordance with the ethical standards of the Institutional Research Committee and with the guidelines set forth in the Declaration of Helsinki. Prior to enrollment, each patient provided written informed consent.

Patients were evaluated preoperatively with regard to skin excess and laxity of the abdominal wall, the position of the umbilicus,[6] and the presence of abdominal surgical scars. Patients with neurologic or musculoskeletal diseases that could cause back and lumbar pain were excluded from the study. Also excluded were patients who had undergone spinal surgery to treat congenital kyphosis or trauma, as well as patients with obstructive or restrictive pulmonary diseases, systemic diseases, or abdominal surgical scars. Patients who were considered current smokers were excluded.

Patients who were generally in good health and who presented with excess abdominal skin, diastasis recti, and substantial muscular weakness of the anterior abdominal wall were invited to participate in the study.

Forty women who presented with back and lumbar pain that interfered with normal activities and who underwent abdominoplasty from January 2008 through December 2011 were evaluated in this prospective study. Patient demographics, including age, body mass index (BMI), number of previous pregnancies, and number of twin pregnancies, were recorded preoperatively.

All patients underwent bidirectional (anteroposterior and lateral) thoracic, lumbar, and lumbosacral radiography performed by a technician who was blinded to the study details. Prior to imaging, patients were asked to remove their shoes and to stand in a relaxed position. All radiographs were evaluated by the study investigators. The presence and severity of thoracic kyphosis and lumbar lordosis were ascertained by means of the Cobb technique.[8-10] Specifically, thoracic kyphosis was determined by measuring the angle between the inferior aspect of the first thoracic vertebra and the inferior aspect of the 12th thoracic vertebra. Lumbar lordosis was determined by measuring the angle between the lines passing through the superior aspect of the first lumbar vertebra and the superior aspect of the sacrum. The lumbosacral angle was defined as the angle between a line passing through the superior aspect of the sacrum and a horizontal line (Figures 1-4).[11]

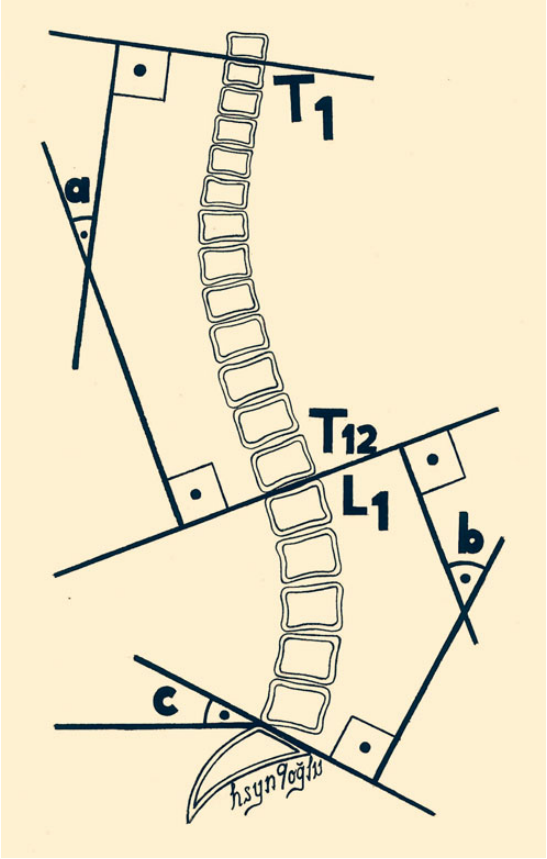

Figure 1. Angles of the vertebral column were measured preoperatively and 6 months after patients underwent abdominoplasty with rectus plication. (A) Thoracic kyphosis was determined by measuring the angle between the inferior aspect of the first thoracic vertebra and the inferior aspect of the 12th thoracic vertebra. (B) Lumbar lordosis was determined by measuring the angle made by lines passing through the superior aspect of the first lumbar vertebra and the superior aspect of the sacrum. (C) The lumbosacral angle was measured as the angle made by a line passing through the superior aspect of the sacrum with a horizontal line.

Preoperative assessments of pain severity, quality of life, and depression severity were conducted by means of a visual analog scale (VAS), the Nottingham Health Profile (NHP), and the Beck Depression Inventory (BDI), respectively. The VAS ranged from 10 (indicating no pain) to 100 (indicating intolerable pain). The NHP included 38 questions pertaining to the following 6 categories: fatigue, pain, emotional reactions,

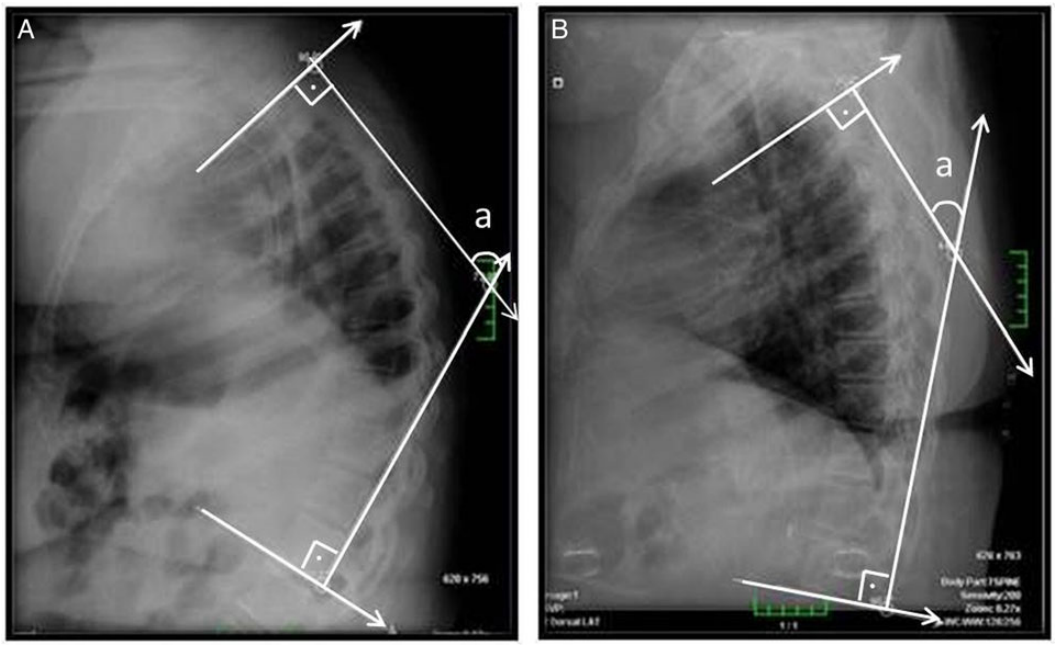

Figure 2. Vertebral-column angles were determined from radiographs obtained from patients in this study. (A) This 56-year-old woman (body weight, 77 kg; body mass index [BMI], 32.04; number of births [parity], 6) presented with abdominal lipodystrophy. The patient underwent excision of 1900 g of tissue and plication of the rectus and the external oblique. Preoperatively, the thoracic kyphosis angle was 56.7 degrees. (B) Six months postoperatively, this angle had decreased to 45.3 degrees.

sleep, socialization, and physical abilities. The BDI comprised 21 questions to quantitatively evaluate depression severity. The same physical therapist performed all assessments. Blank copies of the BDI and NHP are available as Supplementary Material at www.aestheticsurgeryjournal.com.

Surgical Procedures

All patients underwent liposuction, total plication, and supraumbilical resection (ie, lipoabdominoplasty).[12,13] Patients with weakness of the medial external oblique, as determined intraoperatively, also underwent L-shaped plication. All abdominoplasty procedures were performed with the patient under general anesthesia and positioned supine with the arms abducted 90 degrees. Antibiotic prophylaxis (second-generation cephalosporin) was administered intravenously 30 minutes before the initial incision.

For patients with a type 2 deformity of the abdominal wall,[6] a horizontal incision was made 2 cm superiorly from the suprapubic hairline. For patients with a type 3 deformity, the first incision was made from the suprapubic hairline laterally to the anterior superior iliac crest. The abdominal flap was elevated in the myoaponeurotic plane, and dissection proceeded laterally toward the border of the rectus to expose the medial part of the external oblique. The abdominal flap then was elevated to the umbilicus. The new umbilical hole was prepared by making an incision with a pyramidal base by means of a no. 15 scalpel blade. Abdominal flap dissection then continued to the bilateral subcostal margins superolaterally and the xiphoid medially. The conditions of the rectus, linea alba, and external oblique were evaluated intraoperatively, but its width was not measured and patients were classified with regard to aesthetic condition of the myoaponeurotic layer, as described previously.[7] Plication borders for diastasis recti were marked 3 cm from the linea alba bilaterally. Rectus plication was performed from the xiphoid to the umbilicus and from the umbilicus to the symphysis pubis in a continuous fashion with two loop 0 nylon sutures and a round-bodied needle. Following this initial plication, additional primary sutures were placed (absorbable vicryl, size 0). The tensions over the abdominal region and the external oblique were then evaluated. If needed, additional tension was achieved with L-shaped plication of the medial external oblique and anterior abdominal wall by means of nonabsorbable sutures, as described prevoiusly.[7]

Following rectus plication, the patient was moved from the supine to the half-sitting position (30°-45° from horizontal), and tissue resection was conducted. For each patient, the mass of excised tissue was recorded. The new position of the umbilicus then was determined by approximating the abdominal flap on the midline of the suprapubic region, and temporary guide sutures were placed. The guide sutures then were removed, and the tissue around the newly prepared umbilical hole was thinned to produce an aesthetically pleasing cavity at the umbilicus. The umbilicus was adapted to the new hole with polypropylene sutures (size, 2-0) placed as 4 equally

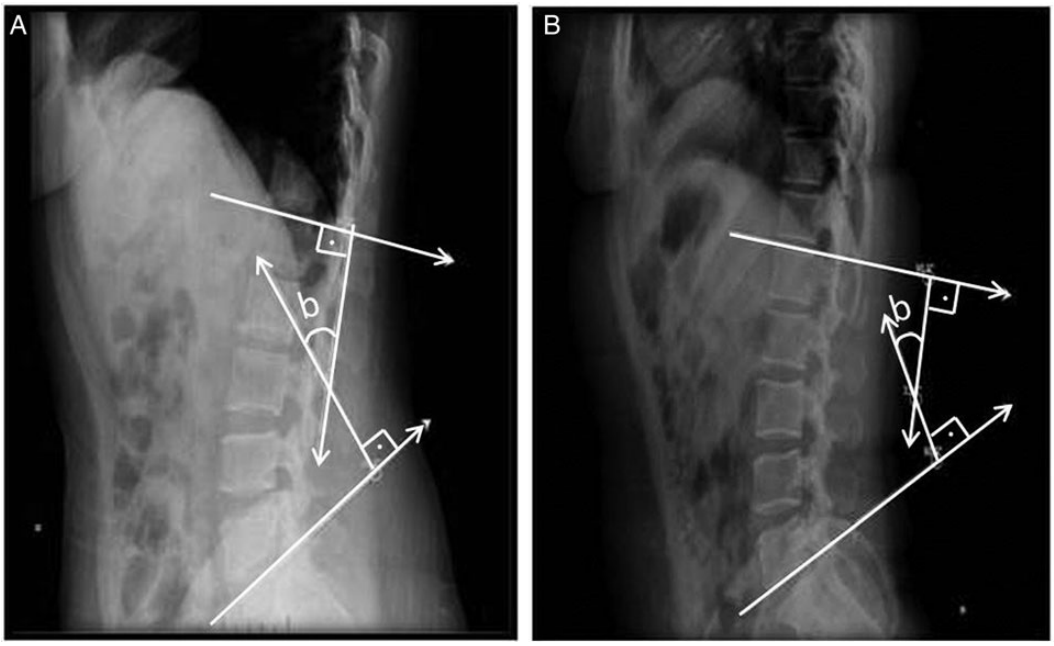

Figure 3. Vertebral-column angles were determined from radiographs obtained from patients in this study. (A) This 38-year-old woman (body weight, 74 kg; BMI, 28.19; parity, 4) presented with abdominal lipodystrophy. The patient underwent excision of 2000 g of tissue and rectus plication. Preoperatively, the lumbar lordosis angle was 46.7 degrees. (B) Six months postoperatively, this angle had decreased to 38.9 degrees.

spaced stitches in a clockwise fashion around the umbilicus (ie, 3:00, 6:00, 9:00, 12:00). Suturing was performed from the base, to the umbilicus, to the abdominal flap. Adjacent deformities, such as those involving the flanks, were treated with liposuction, and dog-ear deformities were excised. Suction drains were placed routinely in all of the patients. After the operation, the patient was taken to the recovery room in the half-sitting position.

Postoperative Care

All patients received antibiotic prophylaxis until postoperative day 5. No patients received thromboembolic prophylaxis. Patients were encouraged to return to mobility at 8 hours postoperatively. Patients were advised to wear an abdominal corset for 1 month postoperatively and were allowed to resume exercise after 1 month. Patients received follow-up once per month. All imaging and assessments carried out preoperatively were repeated at 6 months postoperatively.

Statistical Analysis

SPSS Statistics for Windows (version 13.0, SPSS Inc, Chicago, IL) was applied for preoperative vs postoperative comparisons of vertebral-column angles (ie, thoracic kyphosis, lumbar lordosis, and the lumbosacral angle) and of scores on the VAS, NHP, and BDI. Pre- and postoperative numeric data were compared with the paired *t* test (for parametric statistics) or the Wilcoxon signed-rank test (for nonparametric statistics). Relationships between continuous variables were assessed with Pearson's correlation coefficient. Relationships between categorical variables were evaluated with the chi-square test. The Kruskal-Wallis test was applied for between-group comparisons of patient age, number of previous births, and mass of excised tissue. Statistical significance was defined as $P < .05$.

RESULTS

The mean age of the patients was 43.8 years (standard deviation [SD], 4.7 years; range, 33-48 years). Patients were categorized by BMI: group 1, 18.5 to 24.9 kg/m^2 (normal weight); group 2, 25.0 to 29.9 kg/m^2 (overweight); group 3, 30.0 to 39.9 kg/m^2 (obese); and group 4, >40 kg/m^2 (severely obese). Four of the 40 patients (10%) were in group 1, 12 patients (30%) were in group 2, 21 patients (52.5%) were in group 3, and 3 patients (7.5%) were in group 4 (Table 1). The 16 patients in groups 1 and 2 stated that they had undergone substantial weight loss (mean, 29 kg; range, 13-35 kg) from bariatric surgery (n = 2) and/or a specific diet regimen (n = 14). The patients who underwent bariatric surgery were considered eligible for abdominoplasty at ≥6 months postoperatively. Patients in the other groups stated that they had not undergone massive weight loss. No patient had undergone abdominoplasty previously.

Preoperatively, patients were categorized by abdominal-wall deformity following an evaluation of the abdominal

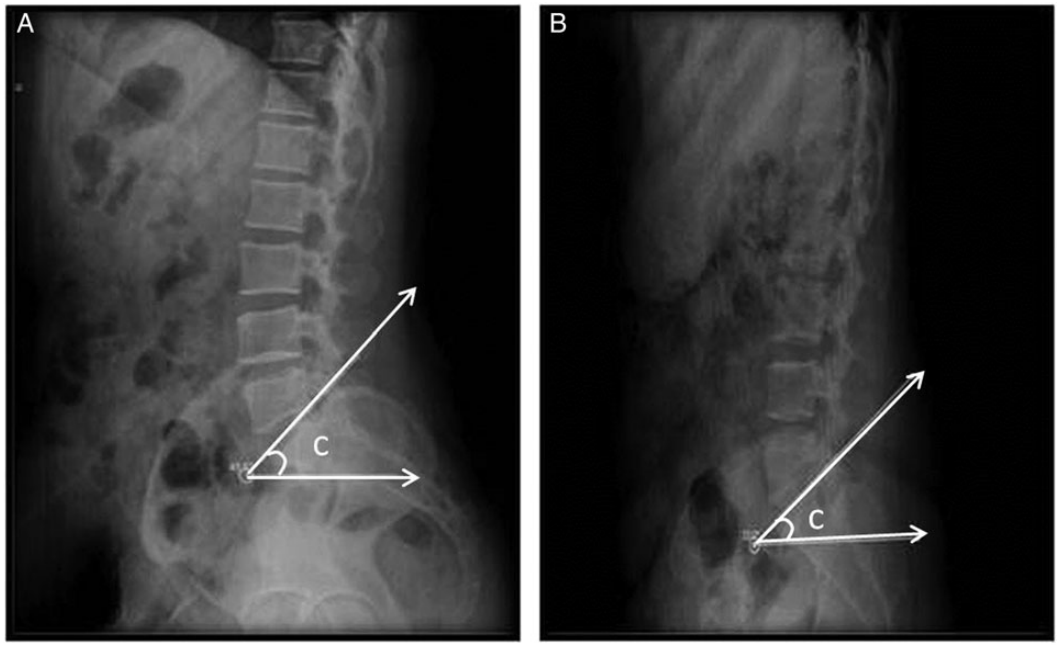

Figure 4. Vertebral-column angles were determined from radiographs obtained from patients in this study. (A) This 34-year-old woman (body weight, 91 kg; BMI, 33.42; parity, 6) presented with abdominal lipodystrophy. The patient underwent excision of 2100 g of tissue, rectus plication, and plication of the external oblique. Preoperatively, the lumbosacral angle was 38.2 degrees. (B) Six months postoperatively, this angle had decreased to 30.4 degrees.

skin and subcutaneous tissue, as described by Nahas.[6] Of the 40 study patients, 35 were classified as having a type 3 abdominal-wall deformity (ie, severely excessive skin), whereas 5 patients were classified as having a type 2 deformity (ie, mild to moderate excess skin and a well-positioned umbilicus; Table 1).[6]

The mean operating time was 2.23 hours (SD, 0.15 hours; range, 2.0-2.5 hours). The average follow-up period was 12 months (SD, 4 months; range, 8-18 months). The mean mass of resected tissue was 1748.9 g (SD, 594.1 g; range, 1000-4060 g). Based on preoperative signs and intraoperative findings regarding the myoaponeurotic layer, all patients in groups 1 and 2, 17 patients in group 3, and 1 patient in group 4 were classified as having a type A myoaponeurotic deformity (ie, diastasis recti associated with pregnancy).[7] These 34 patients underwent rectus plication only. Four patients in group 3 and 2 patients in group 4 were classified as having a type B deformity (ie, abdominal-wall laxity).[7] These 6 patients underwent L-shaped plication of the aponeurosis of the external oblique in addition to rectus plication.

The patients were hospitalized for 2 to 4 days postoperatively. Drains were removed 4 or 5 days postoperatively. No patients experienced major complications. Wound infections occurred in 2 patients, which were managed by dressing changes. The wound infections did not require operative intervention. Two other patients experienced seroma formation. There were no instances of hematoma formation, wound dehiscence, thromboembolism, ileus, or respiratory difficulty. No patient experienced loss of sensitivity in the suprapubic region. Patients resumed daily activities approximately 15 days postoperatively.

Sixteen (40%) of the 40 patients had ≥4 previous pregnancies, and 6 of these patients had a twin pregnancy. Patients with a history of twin pregnancy stated that their back pain had begun during the last 3 months of pregnancy. Because the number of patients in groups 1 and 4 was insufficient to make a statistical comparison (4 patients and 3 patients, respectively), these patients were assessed as 1 group. There were no significant between-group differences in age, number of previous births, and mass of excised tissue ($P \geq .05$ for all; Figure 5).

The findings of the VAS addressing severity of back and lumbar pain indicated that significant improvement occurred postoperatively ($P < .001$; Figure 6, Tables 2 and 3). Similarly, BDI scores indicated that depression was reduced significantly ($P < .001$; Figure 7, Tables 2 and 4), and NHP findings indicated significant improvements in fatigue, pain, and sleep ($P < .001$; Table 2). These findings indicate that abdominoplasty with rectus plication improves quality of life for these patients, presumably owing to substantial reductions in back and lumbar pain.

Radiographs were obtained of each patient while standing still. These static representations of posture enabled precise measurement of the changes in vertebral-column angles that occurred after abdominoplasty with rectus plication. Such

Table 1. Patient Demographics[a]

	Group 1	Group 2	Group 3	Group 4
Mean age ± SD, years (range)[b]	39.0 ± 1.82 (37-41)	43.25 ± 11.84 (23-67)	44.81 ± 11.50 (26-66)	45.67 ± 7.50 (38-53)
Mean no. of births ± SD (range)[b]	3.0 ± 0.81(2-4)	2.91 ± 1.31 (0-4)	3.19 ± 1.72 (0-6)	4.3 3 ± 2.08 (2-6)
Mean mass excised tissue, g (range)[b]	1525 (1200-1650)	1475 (1000-2000)	1800 (1000-4060)	1500 (1380-2350)
AWD type 2, no. of patients	1	1	2	1
AWD type 3, no. of patients	3	11	19	2
MD type A, no. of patients	4	12	17	1
MD type B, no. of patients	0	0	4	2
RP, no. of patients	4	12	17	1
RP and EOAP, no. of patients	0	0	4	2

AWD, abdominal-wall deformity; EOAP, external oblique aponeurosis plication with rectus plication; MD, myoaponeurotic deformity; NS, not significant ($P > .05$); RP, rectus plication. [a]Patients were classified with regard to body mass index (BMI) into 4 groups, as follows: group 1, 18.5 to 24.9 kg/m^2 (normal weight); group 2, 25.0 to 29.9 kg/m^2 (overweight); group 3, 30.0 to 39.9 kg/m^2 (obese); and group 4, >40 kg/m^2 (severely obese). [b]$P > .05$; Kruskal-Wallis test.

an assessment would not have been possible if the patients had been imaged while in motion. Significant improvements in thoracic kyphosis, lumbar lordosis, and the lumbosacral angle were observed postoperatively ($P < .001$; Table 5, Figures 8-10).

DISCUSSION

Excessive weight fluctuations and pregnancy, especially multiple pregnancy, can result in diastasis recti and weakening of the connections between the lateral abdominal muscles and the rectus sheath. This weakening can lead to reductions in intra-abdominal pressure and in pressure over the vertebrae provided by the thoracolumbar fascia. Over time, the affected individual's center of gravity shifts anteriorly along the vertebral column, inducing the spinal extensor muscles to contract, increasing pressure on the intervertebral discs, and causing pain.[14] The rectus abdominus and its connections with other abdominal muscles, especially the external oblique, provide stability to the vertebral column.[15-20] A strong anterior abdominal wall precludes contraction of the spinal muscles, thereby avoiding excess pressure on the intervertebral discs.[14] The results of several biomechanical studies[21-24] have indicated that increased intra-abdominal pressure can augment stability of the spine. Wide rectus plication can improve chronic lumbar pain by accentuating lumbar lordosis and stabilizing the spine.[2,5,25,26]

All patients in this study underwent rectus plication. The outcomes of abdominoplasty with rectus plication included significant improvements in thoracic kyphosis, lumbar lordosis, and the lumbosacral angle ($P < .001$; Tables 2-5). In addition, patients experienced reduced back and lumbar pain. Parity (especially multiparity), obesity,

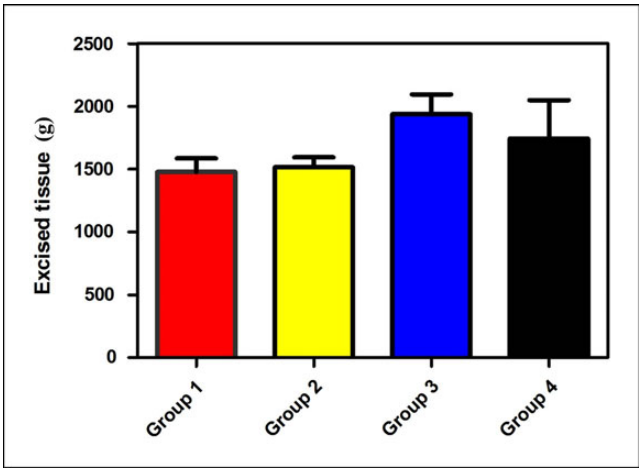

Figure 5. Mean masses (± standard deviation [SD]) of tissue excised from patients in this study during abdominoplasty with rectus plication. Patients were categorized with regard to BMI into the following groups: group 1, 18.5 to 24.9 kg/m^2 (normal weight; n = 4 of 40); group 2, 25.0 to 29.9 kg/m^2 (overweight; n = 12); group 3, 30.0 to 39.9 kg/m^2 (obese; n = 21); and group 4, >40 kg/m^2 (severely obese; n = 3).

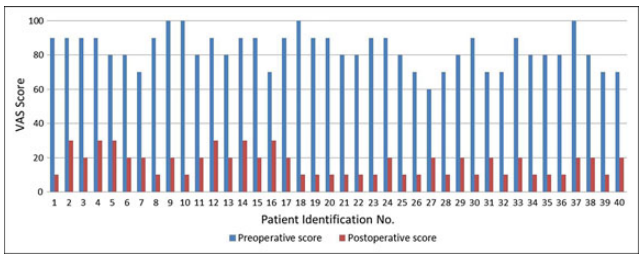

Figure 6. Results of the visual analog scale (VAS) for each patient preoperatively and at 6 months postoperatively. The VAS was scored from 10 (no pain) to 100 (intolerable pain).

Table 2. VAS, BDI, and NHP Scores

	Preoperative Score	Postoperative Score[a]	*P* Value[b]
Mean (± SD) VAS	83.3 ± 10	17 ± 7.2	< .001
Mean (± SD) BDI	15.8 ± 4.8	1.6 ± 1.1	< .001
Mean (± SD) NHP, pain	42.2 ± 11.2	15.6 ± 9.3	< .001
Mean (± SD) NHP, physical activity	33.1 ± 12.5	0 ± 0	NC
Mean (± SD) NHP, socialization	21 ± 15.7	0 ± 0	NC
Mean (± SD) NHP, fatigue	57.9 ± 23.6	3.3 ± 10	< .001
Mean (± SD) NHP, sleep	37 ± 20	1.5 ± 5.3	< .001
Mean (± SD) NHP, emotional reaction	19.3 ± 11.3	0 ± 0	NC

BDI, Beck Depression Inventory; NC, could not be calculated; NHP, Nottingham Health Profile; SD, standard deviation; VAS, visual analog scale. [a]Results were obtained 6 months postoperatively. [b]Wilcoxon signed-ranks test.

Table 3. Changes in VAS Scores

Pain Severity[a]	No. of Patients (%), Preoperatively	No. of Patients (%), Postoperatively[b]
10	0 (0)	18 (45)
20	0 (0)	16 (40)
30	0 (0)	6 (15)
40	0 (0)	0 (0)
50	0 (0)	0 (0)
60	1 (2.5)	0 (0)
70	8 (20)	0 (0)
80	12 (30)	0 (0)
90	15 (37.5)	0 (0)
100	4 (10)	0 (0)

VAS, visual analog scale. [a]VAS from 10 (no pain) to 100 (intolerable pain). [b]Patients were re-evaluated at 6 months postoperatively.

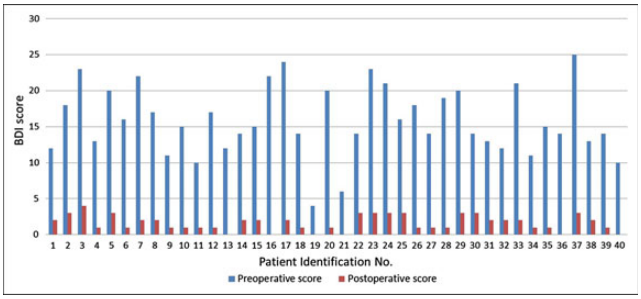

Figure 7. Results of the Beck Depression Inventory (BDI) for each patient preoperatively and at 6 months postoperatively. The BDI was scored as follows: 0-9, minimal depressive symptoms; 10-16, mild depressive symptoms; 17-29, intermediate depressive symptoms; 30-60, severe depressive symptoms.

weakness of the myoaponeurotic layer, and advanced age increase the likelihood of diastasis recti. The primary risk factor for diastasis recti is pregnancy, which typically produces fusiform diastasis along the linea alba.[7] Diastasis recti is more likely to develop in women who have given birth vaginally than in women who underwent cesarean birth.[27,28] This difference may be attributable to excessive deformation of the rectus sheath. Sixteen of the 40 patients in the present study had ≥4 previous pregnancies, and 6 patients had 1 previous twin pregnancy. Structural features of the myoaponeurotic layer were consistent with parity in these patients. Of the 6 patients who had given birth ≥5 times, all required bilateral plication of the external oblique in addition to rectus plication.[7]

We found that minimal overcorrection of the rectus was needed to revise the insertion of the external oblique and to effect biomechanical changes that resulted in augmented stability of the vertebrae and the anterior abdominal wall. The results of this study support the notion that rectus plication changes the angle of the vertebrae by applying increased pressure over the abdomen and increased tension over the thoracolumbar fascia. However, studies of muscle function are needed to validate these findings. We prefer static evaluations of vertebral angles because this is more objective than active motion. Also, previously published studies have used static evaluation method.[29]

Toranto[2] classified patients with lumbar pain into 3 groups: those with muscular spasm, those with herniation of the nucleus pulposus, and those with facet syndrome with or without nerve compression. For patients in any of these groups, Toranto[2] noted that abdominoplasty could be beneficial. In a separate report, Toranto[5] applied magnetic resonance imaging and observed that abdominoplasty with wide rectus plication produced an increase in the intervertebral distance. Moreover, this author found that the contractive power of the lateral abdominal muscles was

Table 4. Changes in BDI Scores

Depression Severity[a]	No. of Patients (%), Preoperatively	No. of Patients (%), Postoperatively[b]
0-9	2 (5)	40 (100)
10-16	22 (55)	0 (0)
17-29	16 (40)	0 (0)
30-60	0 (0)	0 (0)

BDI, Beck Depression Inventory. [a]BDI scale: 0-9, minimal depressive symptoms; 10-16, mild depressive symptoms; 17-29, intermediate depressive symptoms; 30-60, severe depressive symptoms. [b]Patients were re-evaluated at 6 months postoperatively.

Table 5. Changes in Vertebral-Column Angles

	Preoperatively	6 Months Postoperatively
Mean thoracic kyphosis angle (± SD)[a,b]	49.6 (± 8.2)	39.2 (± 5.6)
Mean lumbar lordosis angle (± SD)[a,c]	41.5 (± 5.8)	34.3 (± 3.5)
Mean lumbosacral angle (± SD)[a,d]	47.4 (± 6.5)	41.7 (± 5.8)

SD, standard deviation. [a]$P < .001$ (paired-samples t test). [b]Thoracic kyphosis was determined by measuring the angle between the inferior aspect of the first thoracic vertebra and the inferior aspect of the 12th thoracic vertebra. [c]Lumbar lordosis was determined by measuring the angle made by lines passing through the superior aspect of the first lumbar vertebra and the superior aspect of the sacrum. [d]The lumbosacral angle was defined as the angle between a line passing through the superior aspect of the sacrum and a horizontal line.

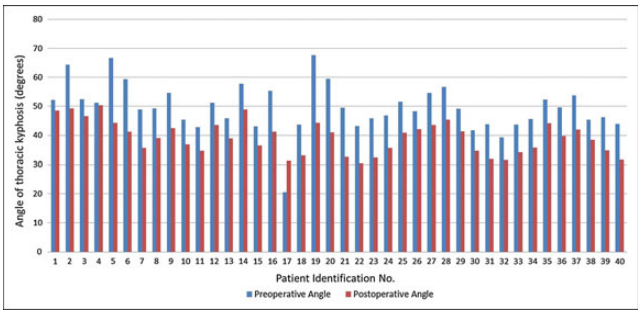

Figure 8. Thoracic kyphosis angles for each patient preoperatively and at 6 months postoperatively.

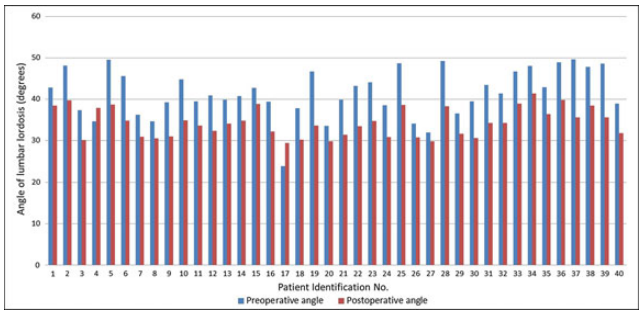

Figure 9. Lumbar lordosis angles for each patient preoperatively and at 6 months postoperatively.

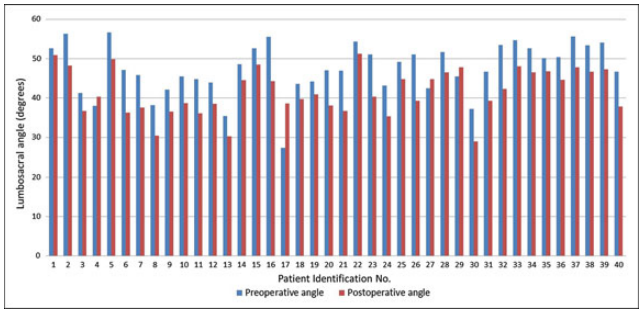

Figure 10. Lumbosacral angles for each patient preoperatively and at 6 months postoperatively.

increased with wide rectus plication, even in the absence of rehabilitative therapy.[5] However, increased venous pressure in the lower extremities developed in some patients as a complication of wide rectus plication.[5]

In a study of 8 women with lumbar pain, Oneal et al[4] demonstrated that abdominoplasty with 90-degree rectus plication (ie, from the lateral edges of the rectus) resulted in long-term relief of pain. However, ileus developed in 1 patient in the early postoperative period, and 3 patients experienced respiratory difficulty.[4] These authors did not discuss the internal traction of the umbilicus and concomitant circulatory problems that could result from extensive rectus plication.[4] Patients provided only verbal descriptions of their lumbar pain (ie, pain levels were not scored on a standardized scale), and long-term radiographic findings of the spinal slope were not presented.[4] Thirty-four of the 40 patients in our study underwent plication of the rectus sheath 3 cm bilaterally from the linea alba, and 6 patients underwent additional plication of the external oblique. No complications, such as increased lower extremity venous pressure or venous thromboembolism, occurred in the present study. We suggest that complications owing to increased intra-abdominal pressure were avoided in our study because extensive rectus plication was avoided.

Rodrigues et al[30] did not find an increase in intra-abdominal pressure following surgical correction of diastasis recti that entailed plication of the anterior rectus sheath. However, these authors evaluated 17 women who had a lower BMI and fewer previous pregnancies compared with our study group. In addition, several authors have found increased intra-abdominal pressure following repair of diastasis recti.[31,32] Although we did not assess intra-abdominal pressure at 6 months postoperatively, othes have demonstrated that the outcomes of rectus plication remain robust at 3, 6, and 12 months postoperatively.[33] Nahas et al[34] and Tadiparthi et al[33] applied computed tomography and ultrasonography, respectively, to demonstrate the persistence of nonabsorbable sutures in patients who underwent rectus plication. Further studies are

warranted to evaluate the persistence of absorbable sutures vs nonabsorbable sutures. In an attempt to further improve the durability of abdominoplasty with rectus plication, we performed additional plication with an absorbable suture placed over the first nonabsorbable suture.

Bayramoglu et al[35] observed that obese patients with weak thoracic muscles frequently experienced chronic back and lumbar pain that could be ameliorated by strengthening the thoracic muscles. Despite a positive correlation between the mass of resected tissue and BMI, no significant correlation was found between the mass of resected tissue and the lumbosacral angle. Therefore, we suggest that increased intra-abdominal pressure following rectus plication is more essential to vertebral stabilization than is the mass of resected tissue (Table 1).[36,37] No patient in the present study underwent panniculectomy without rectus plication. Although we did not assess the effects of panniculectomy alone on vertebral-column angles, we speculate that panniculectomy without rectus plication would not alter the lumbosacral angle. Further study is warranted to address the possible effects on posture of panniculectomy alone.

In a study of 46 patients who underwent abdominoplasty and were evaluated with stabilometry and the Fastrak system, Mazzocchi et al[38] found favorable changes in posture and increased abdominal stabilization at 1 year postoperatively. These authors suggested that postural changes were due in part to psychological improvements in body image and self-confidence.[38] Their finidings are consistent with the results of the present study at 6 months postoperatively (Figures 6-10, Tables 2-5).

Physical manifestations of abdominal lipodystrophy include maceration and dermatitis under the abdominal fold. Abdominal lipodystrophy also is associated with psychological and quality-of-life ramifications, such as limitations with daily physical activities, unfavorable body image, poor self-confidence, and avoidance of social activities. In the present study, it appeared that patients were mildly or moderately depressed preoperatively (BDI score [mean ± SD], 15.8 ± 4.8), and minimally depressed after abdominoplasty with rectus plication (BDI score, 1.6 ± 1.1; $P < .001$). A positive correlation was found between the pre- to postoperative decrease in BDI score and the vertebral-column angles that affect posture. The preoperative VAS score for pain was 83.3 ± 10.0; which decreased significantly, to 17.0 ± 7.2 ($P < .001$), after the surgery. Additionally, NHP findings indicated significant postoperative improvements in the health profiles of the patients in this study ($P < .001$). Similarly, Saariniemi et al[39] demonstrated improvements in quality of life and psychological distress following abdominoplasty.

In a study of 25 patients who underwent bariatric abdominoplasty, Grieco et al[40] found that seroma was the most common complication, affecting 9 patients (36%). Of the 40 patients in our study, seroma developed in 2 (5%). The wound-infection rate measured by Grieco et al[40] was 8% (2 of 25 patients), which is comparable to the wound-infection rate in the present study (5%, 2 of 40 patients).

The present study had several limitations. We compared vertebral-column angles measured from radiographs of patients in our study group with those of the general population because vertebral-column angles of a large, representative population (ie, multiparous women of similar age and BMI) were not available. Men were not included in the present study, and the BMIs of the 40 women enrolled were not distributed normally. In addition, we did not measure intra-abdominal pressure during rectus plication, and we did not perform dynamic imaging of muscles after abdominoplasty. Finally, our study patients did not receive long-term follow-up. Further studies are warranted to evaluate long-term radiographic changes in vertebral-column angles.

CONCLUSIONS

Removal of excess abdominal tissue in conjunction with vertical rectus plication changes the body's center of gravity and decreases pressure over the posterior aspect of the intervertebral discs. Postoperatively, the lateral abdominal muscles function more efficiently, thereby increasing the intra-abdominal pressure and stabilizing the vertebral column. These physiologic changes contribute to the amelioration of back and lumbar pain. Abdominoplasty with rectus plication may be indicated as a non-implant-based surgical approach to treat women with abdominal lipodystrophy, especially multiparous women with substantial abdominal laxity. Our findings indicate significant improvements in posture and quality of life.

Supplementary Material

This article contains supplementary material located online at www.aestheticsurgeryjournal.com.

Acknowledgements

The authors thank Dr Ercan Madenci (Medical Faculty, Department of Physical Therapy and Rehabilitation, Medeniyet University) for his guidance in determining vertebral angles. The authors also thank Dr Hüseyin Dokuzoğlu for providing medical artwork.

Disclosures

The authors declared no potential conflicts of interest with respect to the research, authorship, and publication of this article.

Funding

The authors received no financial support for the research, authorship, and publication of this article.

REFERENCES

1. Tercan M, Bekerecioglu M, Dikensoy O, et al. Effects of abdominoplasty on respiratory functions: a prospective study. *Ann Plast Surg.* 2002;49(6):617-620.
2. Toranto IR. Resolution of back pain with the wide abdominal rectus plication abdominoplasty. *Plast Reconstr Surg*. 1988;81(5):777-779.
3. de Brito MJ, Nahas FX, Bussolaro RA, Shinmyo LM, Barbosa MVFerreira LM. Effects of abdominoplasty on female sexuality: a pilot study. *J Sex Med*. 2012;9(3):918-926.
4. Oneal RM, Mulka JP, Shapiro P, Hing D, Cavaliere C. Wide abdominal rectus plication abdominoplasty for the treatment of chronic intractable low back pain. *Plast Reconstr Surg*. 2011;127(1):225-231.
5. Toranto IR. The relief of low back pain with the WARP abdominoplasty: a preliminary report. *Plast Reconstr Surg*. 1990;85(4):545-555.
6. Nahas FX. A pragmatic way to treat abdominal deformities based on skin and subcutaneous excess. *Aesthetic Plast Surg*. 2001;25(5):365-371.
7. Nahas FX. An aesthetic classification of the abdomen based on the myoaponeurotic layer. *Plast Reconstr Surg*. 2001;108(6):1787-1795, discussion 96-97.
8. He JW, Bai GH, Ye XJ, et al. A comparative study of axis-line-distance technique and Cobb method on assessing the curative effect on scoliosis. *Eur Spine J*. 2012;21(6):1075-1081.
9. Mendoza-Lattes S, Ries Z, Gao Y, Weinstein SL. Proximal junctional kyphosis in adult reconstructive spine surgery results from incomplete restoration of the lumbar lordosis relative to the magnitude of the thoracic kyphosis. *Iowa Orthop J.* 2011;31:199-206.
10. Mac-Thiong JM, Pinel-Giroux FM, de Guise JA, Labelle H. Comparison between constrained and non-constrained Cobb techniques for the assessment of thoracic kyphosis and lumbar lordosis. *Eur Spine J.* 2007;16(9):1325-1331.
11. Tuzun C, Yorulmaz I, Cindas A, Vatan S. Low back pain and posture. *Clin Rheumatol.* 1999;18(4):308-312.
12. Matos WN Jr, Ribeiro RC, Marujo RA, da Rocha RP, da Silva Ribeiro SM, Carrillo Jiminez FV. Classification for indications of lipoabdominoplasty and its variations. *Aesthet Surg J*. 2006;26(4):417-431.
13. Marques A, Brenda E, Pereira MD, de Castro M, Abramo AC. Abdominoplasty with two fusiform plications. *Aesthetic Plast Surg*. 1996;20(3):249-251.
14. Gracovetsky S, Farfan H, Helleur C. The abdominal mechanism. *Spine*. 1985;10(4):317-324.
15. McGill SM, Grenier S, Kavcic N, Cholewicki J. Coordination of muscle activity to assure stability of the lumbar spine. *J Electromyogr Kinesiol*. 2003;13(4):353-359.
16. Vera-Garcia FJ, Elvira JL, Brown SH, McGill SM. Effects of abdominal stabilization maneuvers on the control of spine motion and stability against sudden trunk perturbations. *J Electromyogr Kinesiol*. 2007;17(5):556-567.
17. Hodges PW, Cresswell AG, Daggfeldt K, Thorstensson A. In vivo measurement of the effect of intra-abdominal pressure on the human spine. *J Biomech*. 2001;34(3):347-353.
18. Brown SH, McGill SM. How the inherent stiffness of the in vivo human trunk varies with changing magnitudes of muscular activation. *Clin Biomech (Bristol, Avon)*. 2008;23(1):15-22.
19. Tesh KM, Dunn JS, Evans JH. The abdominal muscles and vertebral stability. *Spine*. 1987;12(5):501-508.
20. Nahhas Rodacki CL, Luiz Felix Rodacki A, Ugrinowitsch C, Zielinski D, Budal da Costa R. Spinal unloading after abdominal exercises. *Clin Biomech (Bristol, Avon)*. 2008; 23(1):8-14.
21. Hodges PW, Eriksson AE, Shirley D, Gandevia SC. Intra-abdominal pressure increases stiffness of the lumbar spine. *J Biomech*. 2005;38(9):1873-1880.
22. Cholewicki J, Juluru K, McGill SM. Intra-abdominal pressure mechanism for stabilizing the lumbar spine. *J Biomech*. 1999;32(1):13-17.
23. Cholewicki J, Juluru K, Radebold A, Panjabi MM, McGill SM. Lumbar spine stability can be augmented with an abdominal belt and/or increased intra-abdominal pressure. *Eur Spine J*. 1999;8(5):388-395.
24. Essendrop M, Andersen TB, Schibye B. Increase in spinal stability obtained at levels of intra-abdominal pressure and back muscle activity realistic to work situations. *Appl Ergon.* 2002;33(5):471-476.
25. McGill SM, Hughson RL, Parks K. Changes in lumbar lordosis modify the role of the extensor muscles. *Clin Biomech (Bristol, Avon)*. 2000;15(10):777-780.
26. Kim HJ, Chung S, Kim S, Shin H, Lee J, Song MY. Influences of trunk muscles on lumbar lordosis and sacral angle. *Eur Spine J.* 2006;15(4):409-414.
27. Zhou JC, Xu QP, Pan KH, Mao C, Jin CW. Effect of increased intra-abdominal pressure and decompressive laparotomy on aerated lung volume distribution. *J Zhejiang Univ Sci B*. 2010;11(5):378-385.
28. Turan V, Colluoglu C, Turkyilmaz E, Korucuoglu U. Prevalence of diastasis recti abdominis in the population of young multiparous adults in Turkey. *Ginekol Pol*. 2011;82(11):817-21.
29. Persson-Bunke M, Czuba T, Hägglund G, Rodby-Bousquet E. Psychometric evaluation of spinal assessment methods to screen for scoliosis in children and adolescents with cerebral palsy. *BMC Musculoskelet Disord*. 2015;16(1):351.
30. Rodrigues MA, Nahas FX, Reis RP, Ferreira LM. Does diastasis width influence the variation of the intra-abdominal pressure after correction of rectus diastasis? *Aesthet Surg J*. 2015;35(5):583-588.
31. Al-Basti HB, El-Khatib HA, Taha A, Sattar HA, Bener A. Intraabdominal pressure after full abdominoplasty in obese multiparous patients. *Plast Reconstr Surg*. 2004;113 (7):2145-2150, discussion 51-55.
32. Graca Neto L, Araujo LR, Rudy MR, Auersvald LA, Graf R. Intraabdominal pressure in abdominoplasty patients. *Aesthetic Plast Surg*. 2006;30(6):655-658.
33. Tadiparthi S, Shokrollahi K, Doyle GS, Fahmy FS. Rectus sheath plication in abdominoplasty: assessment of its longevity and a review of the literature. *J Plast Reconstr Aesthet Surg*. 2012;65(3):328-332.
34. Nahas FX, Ferreira LM, Augusto SM, Ghelfond C. Long-term follow-up of correction of rectus diastasis. *Plast Reconstr Surg*. 2005;115(6):1736-1741, discussion 42-43.

35. Bayramoglu M, Akman MN, Kilinc S, Cetin N, Yavuz N, Ozker R. Isokinetic measurement of trunk muscle strength in women with chronic low-back pain. *Am J Phys Med Rehabil*. 2001;80(9):650-655.
36. Arjmand N, Shirazi-Adl A. Role of intra-abdominal pressure in the unloading and stabilization of the human spine during static lifting tasks. *Eur Spine J*. 2006;15 (8):1265-1275.
37. Stokes IA, Gardner-Morse MG, Henry SM. Intra-abdominal pressure and abdominal wall muscular function: spinal unloading mechanism. *Clin Biomech (Bristol, Avon)*. 2010;25(9):859-866.
38. Mazzocchi M, Dessy LA, Di Ronza S, Iodice P, Saggini R, Scuderi N. A study of postural changes after abdominal rectus plication abdominoplasty. *Hernia*. 2014;18 (4):473-480.
39. Saariniemi KM, Salmi AM, Peltoniemi HH, Helle MH, Charpentier P, Kuokkanen HO. Abdominoplasty improves quality of life, psychological distress, and eating disorder symptoms: a prospective study. *Plast Surg Int*. 2014;2014:197232.
40. Grieco M, Grignaffini E, Simonacci F, Raposio E. Analysis of complications in postbariatric abdominoplasty: our experience. *Plast Surg Int*. 2015;2015:209173.