Aesth Plast Surg (2015) 39:350–358
DOI 10.1007/s00266-015-0483-y

ORIGINAL ARTICLE BREAST

‘‘The Dermal Internal Brassiere Flap,’’ A New Modification of Inferior Pedicle Breast Reduction Technic

Metin Temel[1] · Ali O. Karakaş[2] · Recep Dokuyucu[3] · Arif Türkmen[4]

Received: 5 January 2015 / Accepted: 26 March 2015 / Published online: 17 April 2015

Abstract

Background The inferior pedicle mammaplasty is particularly applied to large breasts with a long sternal notch to nipple distance. The present study reports modifications developed to solve the bottoming-out deformity, the lack of upper pole fullness and the wound healing problems seen at the reverse T-zone, known disadvantages of the inferior pedicle reduction mammaplasty, and evaluates postoperative sensation.

Methods A total of 110 patients with a mean age of 32 underwent the same technique. In this technique, two pairs of quadrangular and triangular flaps were planned from the skin of resection sites. The triangular dermal flaps and quadrangular flaps were suspended from the periosteum of the 2nd and 4th ribs, respectively. The distance from the nipple to inframammary fold was measured at the postoperative 1st month and 1st year. In the postoperative period, a nipple–inframammary fold distance increase of over 2 cm was determined as bottoming-out deformity. Sensation evaluations were performed by subjective and objective tests.

Results The mean sternal notch to nipple distance was 35.00 cm. After operation, the mean distance between the sternal notch and the nipple was 20.00 cm. NAC examination revealed normal sensation in all patients. Whereas the preoperative mean areolar threshold value was 36.70 g/mm^2, the postoperative first-year mean areolar pressure threshold value was 35.50 g/mm^2 ($p < 0.0001$). The preoperative mean nipple pressure threshold value was 25.30 g/mm^2, whereas the postoperative first-year mean nipple pressure threshold value was 26.00 g/mm^2 ($p = 0.5471$). The postoperative first-month mean sternal notch to nipple distance value of the patients was 20.00 cm, whereas the postoperative first-year mean sternal notch to nipple distance value of the patients was 20.00 cm, ($p = 0.0648$). The postoperative first-month mean nipple to submammary fold distance value of the patients was 10.50 cm, the postoperative first-year mean nipple to submammary fold distance value of the patients was 11.00 cm ($p < 0.0001$) There were no patients determined as having bottoming-out deformity. No breast asymmetry was encountered at the late follow-up period. All patients, except the scarred ones, were satisfied with the results.

Conclusion In this study, we achieved an internal fascial reconstruction using a pair of triangular and quadrangular dermal flaps suspended to the rib periosteum. We believe that our modifications will contribute to decreasing the disadvantages of the inferior pedicle breast reduction technique.

Level of Evidence V This journal requires that authors assign a level of evidence to each article. For a full description of these Evidence-Based Medicine ratings, please refer to the Table of Contents or the online Instructions to Authors www.springer.com/00266.

Keywords Reduction mammaplasty · Inferior pedicle · Bottoming-out deformity · Acellular dermal matrix

✉ Metin Temel
prsdrmetintemel@gmail.com; drmetintemel@hotmail.com

1 Department of Plastic and Reconstructive Surgery, School of Medicine, Mustafa Kemal University, Antakya, Hatay, Turkey

2 Department of Plastic and Reconstructive Surgery, Sanliurfa Education and Research Hospital, Sanlıurfa, Turkey

3 Department of Physiology, School of Medicine, Mustafa Kemal University, Antakya, Hatay, Turkey

4 Department of Plastic and Reconstructive Surgery, School of Medicine, Istanbul University, İstanbul, Turkey

Introduction

The most important purpose of reduction mammaplasty is to preserve the aesthetical appearance and function while decreasing volume and weight [1]. The inferior pedicle technique was first described by Ribeiro [2], afterward Courtiss and Goldwyn [3], Robbins [4], Georgiade [5], and Reich [6] also published reports. The excellent preservation of the sensation and the blood supply to the nipple, preservation of breast feeding ability for young patients, the applicability in cases of long sternal notch–nipple distances, which are not suitable for most of the other techniques, and the shortness of the learning curve are the main advantages for the technique [7]. The technique also has some disadvantages such as a longer operative time due to the de-epithelisation process, postoperative perfusion problems due to the tension of the reverse T-zone, the bottoming-out deformity, and lack of projection and upper pole fullness in the long term [8].

Despite its wide use, many modifications have been described to avoid the disadvantages. Most of these modifications focused on decreasing the tension over the reverse T-zone. There are plenty of studies on solutions for the long-term problems, the bottoming-out deformity, and the lack of projection. In this study, we tried to describe the "*The Dermal Internal Brassiere Flap*" technique for suspending the deformed and large breasts to their natural anatomical location by repairing the fascia and reduction process using a pair of dermal flaps, and to review the other modifications applied to the inferior pedicle technique and to evaluate postoperative sensation, bottoming-out deformity of the operated breasts with objective tests.

Materials and Methods

Patients and Methods

A total of 110 patients were operated on using ''*The Dermal Internal Brassiere Flaptechnique*'' between 2010 and 2014 years. The patients were selected according to the following criteria: a sternal notch to nipple distance ≥30 cm and to have such large breasts that increase the possibility of Wise pattern breast reduction. The patients were operated on by the same surgeon (MT). Patients' medical histories were obtained and for the ≥40 aged patients sonography and mammography were performed. Patients with suspicious results were excluded from the study and were referred for further investigation.

Among the operated patients, eighty patients were reached for follow-up control at the postoperative first month and first year. The control photographs were taken at the standard positions, the distance between the areola and the submammary fold was measured and the sensation was evaluated. The submammary fold-nipple distance was determined by measuring the distance between the lower border of the areola and the inframammary fold while the patient was in an upright standing position. An increase of the distance more than 2 cm between the postoperative first-month measurement and first-year measurement was considered as bottoming-out deformity [9]. Sensation was assessed by the same examiner. The sensation evaluations were performed by subjective and objective tests. For the subjective evaluation, the patients were questioned about nipple–areola complex (NAC) sense changes and were asked to express the NAC sensation as "same", "worse", or "better" as for before and after the breast reduction surgery. Additionally, the erectile response to each nipple to tactile stimulation was assessed using a wisp of cotton wool.

For the objective evaluation, the Semmes–Weinstein monofilament test was used [10], [11]. Five points were tested on each NAC. These points included the nipple and four cardinal points on the areola at 12, 3, 6, and 9 clockwise. Pressure thresholds were measured with a set of 20 Semmes–Weinstein monofilaments (Smith and Nephew Rolyan, Menomonee Falls, WI, USA). The test was performed in a standard way was recommended by the manufacturer's note. The area was considered insensate if pressure was not sensed when the (6.65) monofilament was applied. The values were converted to a measured stress (g/mm^2) [11].

Surgical Technique

All patients were administered 2nd generation cephalosporin prophylaxis, preoperatively. A single dose of –s.c. Clexane 0.3 I.U.(Aventis Pharma San. and Tic. Ltd.Şti) was given for patients with coagulative risks. The operation plan was carried out while the patient was up-standing and the upper extremities were pulled behind the back aspect of the trunk of the patient. Basic landmarks, including the distance between the NAC and mid-clavicular line, the mid-sternal line, the anterior axillary line and the breast meridians were drawn preoperatively (Fig. 2A1–A5). For locating the new nipple place at 19–21 cm, the incision lines were drawn by a keyhole device according to the breast size. The distance from the mid-sternal line to the midpoint of the inferior pedicle base and the pedicle width was determined as 9–11 and 7–10 cm, respectively. For certain patients with lateralisation of the breast meridian due to medial fullness, the breast meridian was determined as for the mid-clavicular line to avoid lateralisation of the NAC (Fig. 2A3). The inframammary fold was drawn by transposing up the breasts. The inframammary fold line

was revised so as to be 1–2 cm above the previously drawn inframammary fold to avoid displacement of the inframammary fold due to suspension while the patient was supine for the operation. A pedicle flap arising from the inferior chest wall was planned as for to reach the suture line of the reverse T connection zone to avoid circulatory compromise due to flap tension (Fig. 1a, b).

In this technique, a pair of dermal flaps was planned over the zone that was removed in the traditional technique. The triangular dermal flap starts from 2 cm below the proposed NAC and is planned as an equilateral triangle with 4–6 cm edge lengths, the lower aspect must be planned to be at least 4 cm above the inframammary fold. The quadrangular flap is planned to be started 2–3 cm above the inframammary fold and to have 3–5 cm length and 3–5 cm width (Fig. 1a–c). The Wise pattern skin excision lines must be planned not to extend the anterior axillary line, on the edge. Under general anesthesia, the excision zones are infiltrated with 500 ml saline including 50 ml of 5 % bupivacaine and 1 mg of epinephrine. Then, the incision lines are marked by scalpel to refine the lines. The breast under tourniquet tension provides an easy de-epithelisation. An areolar diameter of 3.6–4.0 cm is marked with an areola marker (Areola Marker, Trimed®). Most of the de-epithelisation is done by the electric dermatome, and the details are completed by a no. 20 scalpel. Afterward, the excess breast tissue is removed from the suprafascial layer. The lateral and medial flaps are raised with 3–4 cm thickness. The superior flaps are undermined through the mid-clavicular line until the 2nd rib, at the level of pectoralis fascia, a web is formed (Fig. 1d). The connections of the dissected line between the medial and lateral chest wall are preserved. Thus, the medial or lateral dislocations of the suspended flap are avoided. Below this web, the medial pair of the triangular dermal flaps are suspended 2–4 cm laterally, then the lateral pair of aforementioned is placed 4–6 cm far away according to the medial flap adaptation, to the 2nd rib periosteum, the quadrangular flap pairs are sutured with a 4–6 cm distance to each other to the 4th rib periosteum via 0 or 1 no. polypropylene (Fig. 1e, f). The displacements of the breast axis may be avoided by placing the web to the breast meridian and providing a precise dissection while composing the web. Also, by the preservation the fascial connections through the medial and lateral flaps, the upper pole fullness of the breast tissue may be provided. After

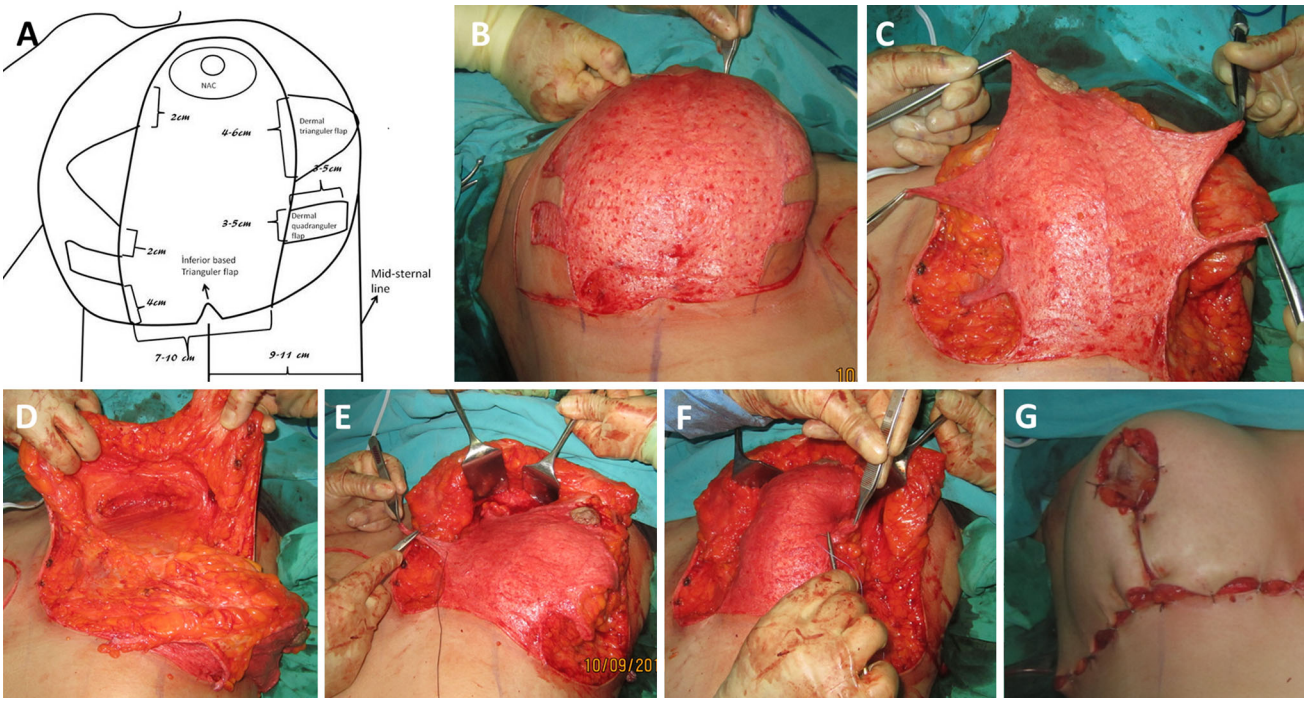

Fig. 1 The diagram of the dermal flaps in the right breast. **a** The inferior pedicle width is planned for 7–10 cm and 9–11 cm from the mid-sternal line, the 3–5 cm sized quadrangular dermal flap is planned 4 cm above the inframammary fold, the triangular dermal flap with 4–6 cm equilateral edges is planned 2 cm above the quadrangular flap. It is necessary to locate the triangular flap 2 cm distally to the NAC to avoid circulatory compromise. **b** The completion of de-epithelisation. A triangular and inferiorly based flap with 1–2 cm edge length is planned at the midpoint of the inferior pedicle to provide the solution for the reverse T-zone circulatory problems. **c** Dermal triangular and quadrangular flaps are shown. **d** The suprafacial dissected tunnel through the mid-clavicular line is seen. The fascial connections of the medial and lateral flaps are preserved. **e**, **f** The fixation of the dermal flaps to the 2nd and 4th rib periosteum. **f** The view of the right breast after the main sutures

suspension, precise bleeding control is completed by bipolar cautery. A hemovac drain is placed for each breast, under the pedicle. Then, the subdermal and dermal sutures are placed (Fig. 1g). By this technical modification, the tension of the reverse T-zone, the early period circulatory problems and the late period bottoming-out deformity problems are avoided. The drains are removed at the postoperative 2nd or 3rd days. The dermal sutures are removed at the 10th or 14th postoperative days. Additionally, a supporting medical brassiere is used for the first 4th and 6th postoperative weeks.

Illustrative Case Reports

Case 1

A 28-year-old, single patient presented with complaints of large breasts, neck and back pain and difficulty finding appropriately sized clothes. While the patient was single and had a 30 cm sternal notch to nipple distance, an inferior pedicle reduction mammaplasty was planned. The nipple axis was displaced laterally due to the medial fullness of the breasts. Therefore, the landmark lines were drawn over the breast meridian, proposed as normal. The new sternal notch–nipple distance was planned to be 19 cm and drawn by a keyhole device (Fig. 2A1–A5). The early postoperative view of the patient is seen (Fig. 2B1–5, C1–C5). The nipple to submammary distance was not measured because of the early postoperative period. Nipple sensation was normal. The results were satisfactory for the patient.

Case 2

A 25-year-old patient presented with complaints of large breasts. The patient had 33 a cm sternal notch to nipple distance. The preoperative and late postoperative views are seen (Fig. 3).

Case 3

A 45-year-old patient was suffering from large breast. She was married and had three births. She had a 32 cm sternal notch to nipple distance. The late postoperative views are shown (Fig. 4).

Case 4

A 37-year-old patient had large breasts and neck and back pain. The anamnesis revealed that she had 4 births and all had breastfed. The sternal notch to nipple distance was 36 cm on the right breast and 35 cm on the left one. The preoperative and late postoperative views are seen (Fig. 5).

Statistical analysis

All statistical analyzes were performed using GraphPad Prism V.5.0 (Graphpad Software Inc., CA, USA). The distribution between the groups was assessed by a Kolmogorov–Smirnov test. The values within the group were not regular so the results were assessed by the Wilcoxon test among the non-parametric tests (for paired samples). The preoperative and postoperative first-year values of the areolar pressure threshold and nipple pressure threshold parameters were assessed by non-parametric Wilcoxon test (for paired samples).

The sternal notch to nipple and the nipple to submammary fold distance values at the postoperative first month and the first year were assessed by non-parametric Wilcoxon test (for paired samples). $p < 0.05$ was considered as significant.

Results

Eighty consecutive patients were entered into this study with a complete follow-up. The mean age of patients was 32 (20–45) years. Among the patients, eighteen of them were unmarried and sixty-two of them experienced at least one birth and breastfeeding. The BMI of the patients were between 20.2 and 30.3 kg/m^2 (average, 26.6 kg/m^2) and most of the patients were in the overweighted category. The mean sternum to nipple distance was 35.00 (30.00–39.00) cm. Furthermore, the mean amount of tissue resected per patient was 1250 g (range 1100–1950 g). The mean follow-up period was 32 months (between 12 and 50 months) (Table 1). Retraction and upward displacement of the inframammary fold due to the pulling effect of the dermal flaps were the most encountered problems in the early postoperative period. No hematoma, seroma, or infection was encountered at the early postoperative period. Neither NAC nor flap necrosis occurred. Wound healing was uneventful in all patients except three. These three patients, who were operated on before the addition of the triangular flap to the reverse T-zone, had dehiscence at the reverse T-zone and were treated by dressings without surgery. Two patients had hypertrophic scarring at inter mammary intersection and lateral to the breasts and the patients were treated with steroid injection and silicon sheet application to the scarring. The postoperative first-year subjective sensation assessment revealed that the 56 patients had "better" sensation and 23 patients had the "same" sensation in comparison with the preoperative period. Only 1 patient complained of a reduction in sensation. All patients had a positive erectile response to touch. The physical examination of the patients revealed the majority of patients experienced improved nipple–

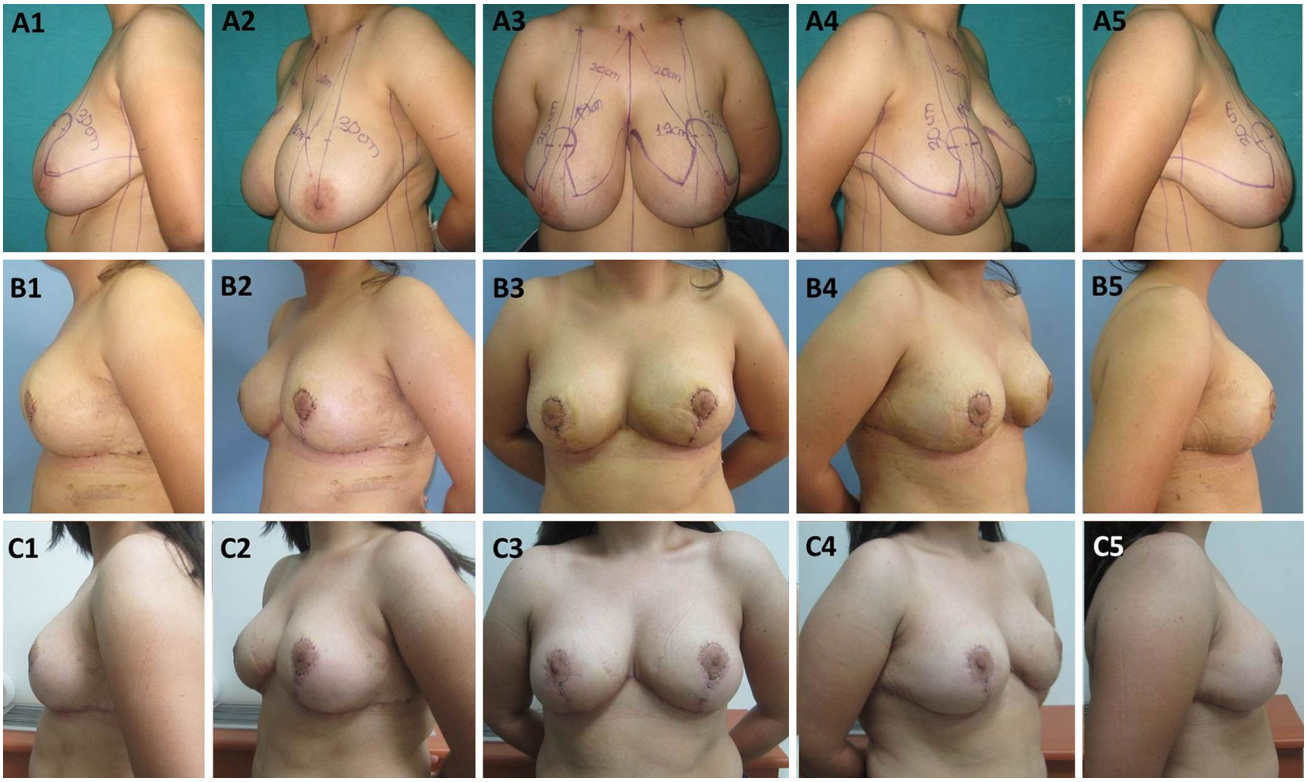

Fig. 2 The patient had a 30 cm sternal notch to nipple distance. *A1–A5* The preoperative left lateral, left oblique, anterior, right oblique, right lateral views. *B1–B5* Postoperative 15th day, left lateral, left oblique, anterior, right oblique right lateral views. *C1–C5* Postoperative 1st month left lateral, left oblique, anterior, right oblique right lateral views

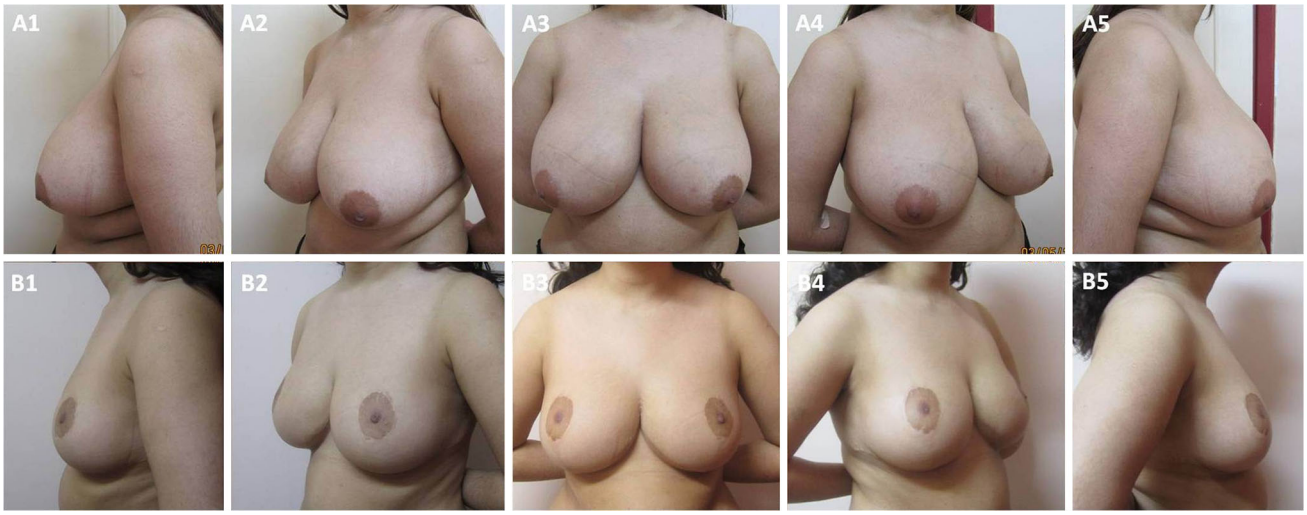

Fig. 3 A 25-year-old patient had a 33 cm sternal notch–nipple distance. *A1–A5* Preoperative, left lateral, left oblique, anterior, right oblique right views. *B1–B5* Postoperative one and a half year left lateral, left oblique, anterior, right oblique right views

areolar sensation postoperatively (Table 2). Although the preoperative mean areolar threshold value was 36.70 (30.20–53.40) g/mm^2, the postoperative first-year mean areolar pressure threshold value was 35.50 (30.10–46.50) g/mm^2. This difference was significant ($p < 0.0001$). Although the preoperative mean nipple pressure threshold value was 25.30 (21.30–30.20) g/mm^2, the postoperative first-year mean nipple pressure threshold value was 26.00 (22.10–30.20) g/mm^2. This difference was not significant ($p = 0.5471$). The postoperative first-month mean sternal notch to nipple distance value of the patients was 20.00 (18.00–23.00) cm, whereas the postoperative

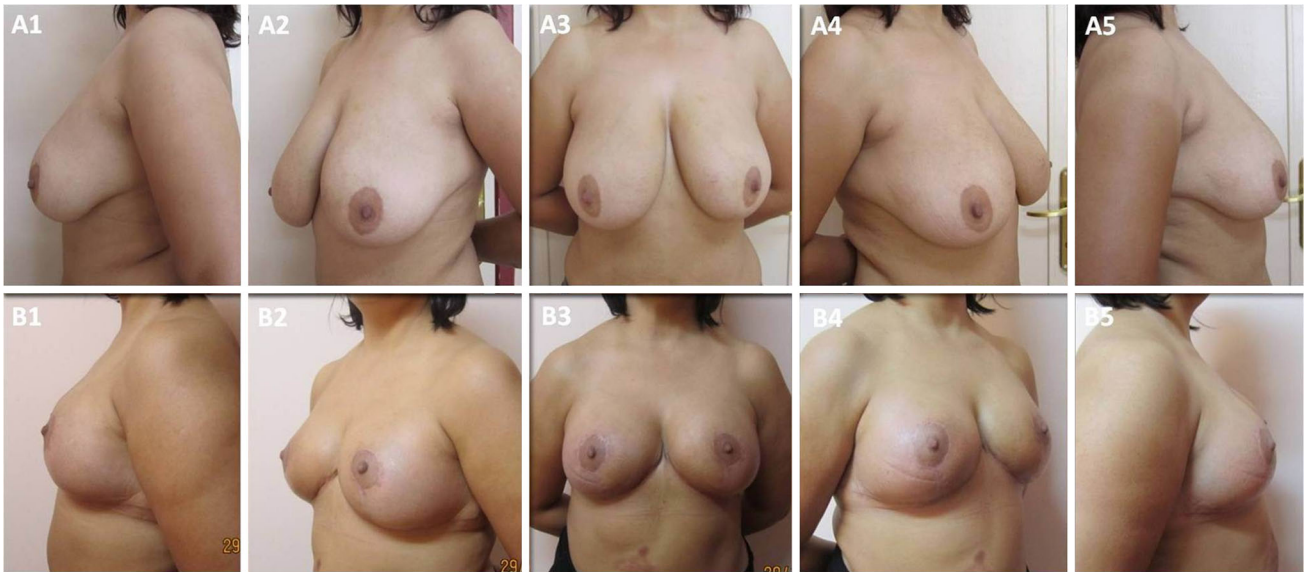

Fig. 4 A 45-year-old patient had a 32 cm sternal notch to nipple distance. *A1–A5* Preoperative, left lateral, left oblique, anterior, right oblique right views *B1–B5* Postoperative 1st year, left lateral, left oblique, anterior, right oblique right views

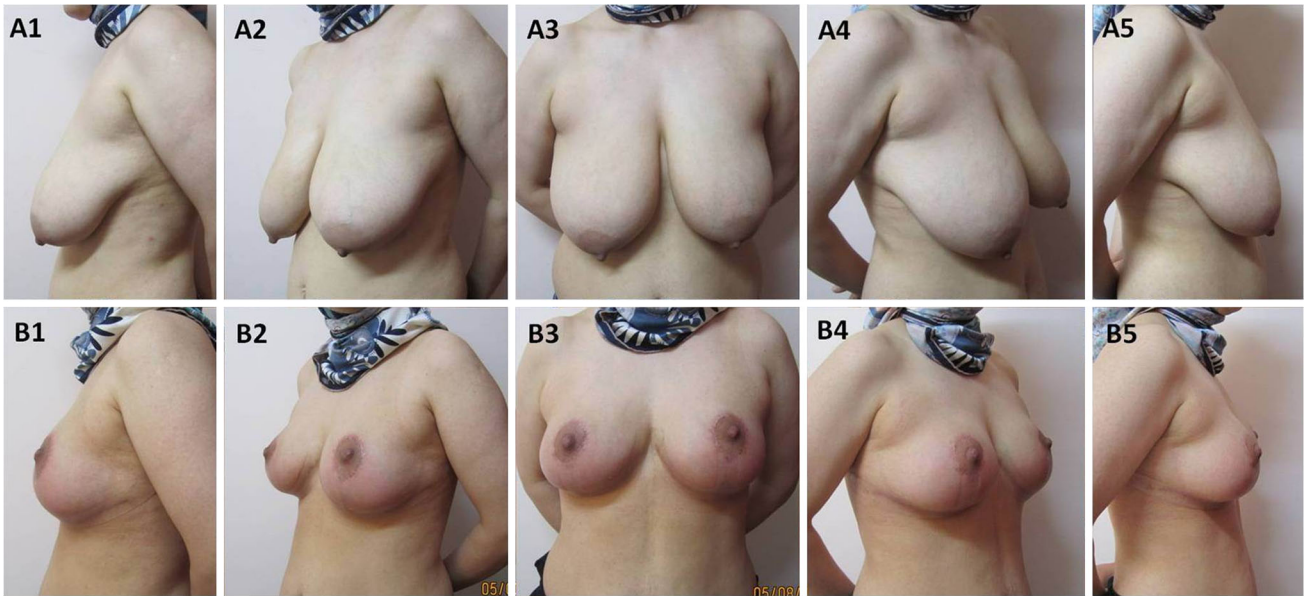

Fig. 5 A 37-year-old patient had a 36 cm on the right breast and a 35 cm on the left sternal notch to nipple distance. *A1–A5* Preoperative, left lateral, left oblique, anterior, right oblique right views. *B1–B5* Postoperative one and a half year left lateral, left oblique, anterior, right oblique right views

first-year mean sternal notch to nipple distance value of the patients was 20.00 (18.00–23.00) cm, an insignificant difference ($p = 0.0648$). The postoperative first-month mean nipple to submammary fold distance value of the patients was 10.50 (10.00–12.00) cm, whereas the postoperative first-year mean nipple to submammary fold distance value of the patients was 11.00 (10.40–12.50) cm, a significant difference ($p < 0.0001$) (Table 3). For all patients, there were not any nipple to submammary distance more than 2 cm, as a result no bottoming-out deformity was considered. No breast asymmetry was encountered at the late follow-up period. All patients, except the scarred ones, were satisfied with the results.

Discussion

The inferior pedicle technique is a secure and applicable to patients who have a nipple to sternal notch distance ≥30 cm and nipple sensation is preserved, compared with

Table 1 Patient data

The number of operated patients	110
The number of patients who were reached at postoperative 1st month and 1st year	80
Age (mean)	32 years (20–45)
Body mass index (mean)	26.6 (20.2–30.3) kg/m^2
Weight resected per patient (mean)	1250 g (range 1100–1950 g)
Unmarried patient/married patient	18/62
Follow-up period	32 (12–50) months

Table 2 Subjective assessment of preoperative and postoperative sensation NAC

	Postop. 1st month	Postop. 1st year
Better	43	56
Same	36	23
Worse	1	1
Patient with erectile response to touch	74	80

Table 3 Objective assessment of preoperative and postoperative sensation NAC and breast measurements

	Preoperative	Postop.1st month	Postop. 1st year	*p* value
Areolar pressure threshold (g/mm$^{2)}$ (median, min−max)	36.70 (30.20–53.40)	46.55 (30.10–59.30)	35.50 (30.10–46.50)	<0.0001*
Nipple pressure threshold (g/mm$^{2)}$ (median, min–max)	25.30 (21.30–30.20)	29.10 (21.20–39.80)	26.00 (22.10–30.20)	(0,5471) NS*
Sternal notch to nipple distance (cm) (median, min−max)	35.00 (30.00–39.00)	20.00 (18.00–23.00)	20.00 (18.00–23.00)	(0,0648) NS**
Nipple to submammarian fold distance(cm) (median, min−max)	19.10 (18.10–23.60)	10.50 (10.00–12.00)	11.00 (10.40–12.50)	<0.0001**

Wilcoxon signed-rank test

NS not significant

* *p* values are given as preoperative values versus values 1 year postoperatively

** *p* values are given as postoperative 1 month values versus values 1 year postoperatively

other breast reduction techniques [12, 13]. The long operative time due to de-epithelisation, tension of the reverse T-zone as seen in all Wise pattern incisions [14], lack of medial fullness, poor projection and the bottoming-out deformity, are the major disadvantages of the technique. The main cause of these deformities is the change in gravity center of the breast as a result of weakening or division of the suspensory ligaments, due to the gravity effect. A number of inferior pedicle modifications have been described such as plication and suspension of the pedicle [15], dermis originated suspensory flaps [16–21], and the suspension of the breast tissue by acellular dermal matrix [22], as possible solutions for these problems. There is an early foreign body reaction risk with acellular dermal matrix breast tissue suspension and a late risk of calcification and falsification effect of the calcification on mammography [22].

Pennington [15] has performed plication and suspension of the pedicle but later many modifications have been added [17–21]. In spite of the suspension of all breast tissue, only the proximal aspect suspension of the pedicle results in loss of superior fullness of the breast. Additionally, the pectoral muscle fascia as the suspension site results in dehiscence at the late period. Furthermore, it is a disadvantage to use absorbable sutures for suspension. The author reported circulatory problems of the nipple in 2 or 3 cases, probably the reverse plication of the inferior pedicle led to circulatory compromise due to the increase of

tension over the perforators [17]. In this technique we do not perform any suturing over the pedicle while performing suspension by the dermal flaps, thus we did not encounter any circulatory problem of the nipple. Therefore, we used non-absorbable polypropylene suture for fixation to enhance long-term durability.

While the "dermal cage" technique of Zic et al. [16] and the study of Aydın et al. [20] have some similarities with our study, the planning of the dermal flap at the inferior pole of the breast will lead to the downward displacement of the superior pole of the breast over time. Using pectoralis fascia as the suspension zone may result in pain due to pectoralis muscle movements at the early period and the suspension may be weakened due to the gravity effect over the fascia. Their description of wound healing problems is the poor aspects of the same technique. Additionally, they have not mentioned neither the connections between the lateral and medial flaps and the thoracic base nor fascial bands, which may be referred as a technical deficiency. In this study, we aimed to solve these problems by suspending the lower and upper pole of the breast tissue by the pairs of triangular and quadrangular dermal flaps to the 2nd and 4th rib periosteum via non-absorbable sutures. We tried to standardize the localisation of the dermal flaps. Additionally, we avoided the lateral or medial dislocations of the breast by inserting the pedicle into a tunnel. Therefore, we think that, we reconstructed the suspensory ligaments of the breast and provided an internal brassiere by protecting the lateral fascial connections and these four dermal flaps. For avoiding the tension over the reverse T-zone and dehiscences, we planned the vertical length of the flaps to be 5 or 6 cm instead of 8 cm, and added an inframammary zone-based triangular flap instead of weak blood supplied regions of the reverse T-zones. Also, due to the inferior pedicle region and the de-epithelisation of the dermal flaps a longer operative time is reported in the same studies. In this study, we used the electric dermatome to decrease the de-epithelisation time, and the mean operative time was 1.5 h.

There are variable studies in the literature about the esthetic evaluations of the breast. Among these studies, the ratio of 45:55, that was developed by Malucci et al. [23], seems to be an easier technique, but if the study is investigated, it will be seen that the models have been evaluated via unstandardized photographs. While evaluating the photographs, one will consider that the models are typically posed with arched backs, retracted shoulders with variable arm positions. Such a measurement will affect the ratios directly, and also will affect the upper and lower pole ratios. However, we photographed the patients in five standardized positions with no tension on the chest wall, which means that the patient is in a neutral position; additionally, our measurement technique was not changed due to the patient's position. Therefore, we believe that these ratios are not appropriate for evaluating the bottoming-out deformity. We used an objective criteria while determining the bottoming-out deformity as the distance increase between the inferior margin of the NAC and submammary sulcus $\geq$2 cm at the 1st postoperative year. The sternal notch to nipple and the nipple to submammary fold distance values at the postoperative first month and the first year were compared statistically and the difference was not significant and was significant, respectively. In other words, no laxity occurred after suspension. We attribute these results to the reconstruction of the breast fascia. As a result, no bottoming-out deformity occurred in any patient. Individually, none of the patients had any increase of nipple–submammary distance of more than 2 cm, but the first postoperative month and first postoperative year distance value increase was statistically significant. Probably the most encountered late postoperative deformity of the inferior pedicle reduction technique, the bottoming-out deformity would be inevitable if the four-point suspension would not be performed in this technique. Therefore, we believe that we need time to assess the late period results.

The previous studies stated that NAC sensitivity was better preserved with the inferior pedicle reduction technique compared to the superior pedicle reduction technique, and the resected quadrant was more important than the resected tissue amount for sensitivity preservation [12, 13]. Furthermore, it is reported that the both the inferior and medial pedicle techniques provide an equal level of NAC sensitivity preservation [24, 25]. In this study, as a result of the subjective evaluation tests, only one patient presented postoperative "Worse" NAC sensation as compared with the preoperative period. Twenty-three patients presented "Same" postoperative sensation and 56 patients presented "Better" postoperative sensation as compared to preoperative NAC sensation. Furthermore, the erectile function of the nipples was totally conserved. As to the Semmes–Weinstein test performed at the preoperative period and the postoperative first year, the areolar threshold values showed that areolar sensation existed under lesser pressure and the nipple pressure threshold value was the same, in other words, there was not any sensation lost (Tables 2, 3).

Prevention of the increased distance between the nipple and inframammary fold, the long durability due to both upper pole and the flap base suspension, the lesser weakening and loosening due to the use of the 2nd and 4th rib periosteum for suspension compared to the other techniques are the advantages of our technique. Additionally, the compromise of circulation and wound healing disturbances at the early period, the preservation of NAC sensation, providing upper pole fullness at the late period by internal brassiere formation and avoiding bottoming-out

deformity are the benefits. The lateral and the medial displacement of the breast tissue is avoided via forming a tunnel by the internal brassiere technique. Better projection is provided by the inhibition of lateral bulging. Also, by this technique, the late onset of ptosis is avoided so the nipple–submammary fold distance is decreased. The intraoperatively dissected breast fascia is reformed.

The main disadvantage of this technique is the learning curve, which decreases with the time and the elongation of the operative period due to the suspension process. Our knowledge will be enhanced by late results. We did not encounter any complications of the inferior pedicle reduction technique at the early period.

Conclusion

In this study, we achieved an internal fascial reconstruction using a pair of triangular and quadrangular dermal flaps suspended to the rib periosteum while preserving their fascial connections. In addition, wound healing problems were avoided by transferring a richer blood supplied flap to the reverse T-zone. We believe that our modifications will contribute to reduce the disadvantages of the inferior pedicle breast reduction technique.

Acknowledgments This research received no specific grant from any funding agency in the public, commercial, or not-for-profit sectors.

Conflict of interest All named authors hereby declare that they have no conflicts of interest to disclose. None of the authors have a financial interest in any of the products, devices, or drugs mentioned in this article.

Ethical Approval All procedures performed in studies involving human participants were in accordance with the ethical standards of the institutional research committee and with the 1964 Helsinki declaration and its later amendments or comparable ethical standards.

References

1. Abramson DL et al (2005) Improving long-term breast shape with the medial pedicle wise pattern breast reduction. Plast Reconstr Surg 115(7):1937–1943
2. Ribeiro L (1975) A new technique for reduction mammaplasty. Plast Reconstr Surg 55(3):330–334
3. Courtiss EH, Goldwyn RM (1977) Reduction mammaplasty by the inferior pedicle technique. An alternative to free nipple and areola grafting for severe macromastia or extreme ptosis. Plast Reconstr Surg 59(4):500–507
4. Robbins TH (1977) A reduction mammaplasty with the areola-nipple based on an inferior dermal pedicle. Plast Reconstr Surg 59(1):64–67
5. Georgiade NG et al (1979) Reduction mammaplasty utilizing an inferior pedicle nipple-areolar flap. Ann Plast Surg 3(3):211–218
6. Reich J (1979) The advantages of a lower central breast segment in reduction mammaplasty. Aesthetic Plast Surg 3(1):47–56
7. Hall-Findlay EJ (2002) Pedicles in vertical breast reduction and mastopexy. Clin Plast Surg 29(3):379–391
8. Yuksel F et al (2012) Experience with vertical mammaplasty: advantages and drawbacks of Hall-Findlay's superomedial pedicle technique and improving the results by adding modifications to the technique. Aesthetic Plast Surg 36(6):1329–1333
9. Widgerow AD (2005) Breast reduction with inferior pedicle fascial suspension. Aesthetic Plast Surg 29(6):532–537 discussion 538-9
10. Weinstein S (1993) Fifty years of somatosensory research: from the Semmes-Weinstein monofilaments to the Weinstein Enhanced Sensory Test. J Hand Ther 6(1):11–22 discussion 50
11. Levin S, Pearsall G, Ruderman RJ (1978) Von Frey's method of measuring pressure sensibility in the hand: an engineering analysis of the Weinstein-Semmes pressure aesthesiometer. J Hand Surg Am 3(3):211–216
12. Schlenz I et al (2005) Alteration of nipple and areola sensitivity by reduction mammaplasty: a prospective comparison of five techniques. Plast Reconstr Surg 115(3):743–751 discussion 752–4
13. Hamdi M et al (2001) A prospective quantitative comparison of breast sensation after superior and inferior pedicle mammaplasty. Br J Plast Surg 54(1):39–42
14. Wise RJ (1956) A preliminary report on a method of planning the mammaplasty. Plast Reconstr Surg (1946) 17(5):367–375
15. Pennington DG (2006) Improving the results of inferior pedicle breast reduction using pedicle suspension and plication. Aesthetic Plast Surg 30(4):390–394
16. Zic R et al (2013) The "dermal cage": a modification of the inferior pedicle breast reduction. Aesthetic Plast Surg 37(2):364–371
17. Echo A, Guerra G, Yuksel E (2011) The dermal suspension sling: shaping the inferior pedicle during breast reduction. Aesthetic Plast Surg 35(4):608–616
18. Frey M (1999) A new technique of reduction mammaplasty: dermis suspension and elimination of medial scars. Br J Plast Surg 52(1):45–51
19. Baumeister RG (2003) Curtain type combined pedicled reduction mammoplasty with internal suspension for extensive hypertrophic and ptotic breasts. Br J Plast Surg 56(2):114–119
20. Aydin H et al (2003) Reduction mammaplasty using inferior pedicle technique combined with dermal suspension. Plast Reconstr Surg 111(3):1362–1363
21. Rubin JP, Gusenoff JA, Coon D (2009) Dermal suspension and parenchymal reshaping mastopexy after massive weight loss: statistical analysis with concomitant procedures from a prospective registry. Plast Reconstr Surg 123(3):782–789
22. Brown RH, Izaddoost S, Bullocks JM (2010) Preventing the "bottoming out" and "star-gazing" phenomena in inferior pedicle breast reduction with an acellular dermal matrix internal brassiere. Aesthetic Plast Surg 34(6):760–767
23. Mallucci P, Branford OA (2012) Concepts in aesthetic breast dimensions: analysis of the ideal breast. J Plast Reconstr Aesthet Surg 65(1):8–16
24. Jaspars JJ et al (1997) The cutaneous innervation of the female breast and nipple-areola complex: implications for surgery. Br J Plast Surg 50(4):249–259
25. Mofid MM et al (2002) Quantitation of breast sensibility following reduction mammaplasty: a comparison of inferior and medial pedicle techniques. Plast Reconstr Surg 109(7):2283–2288